

Case Report

# Primary Hyperparathyroidism and its management in a woman with Hereditary Long QT syndrome.

Raymond Kennedy<sup>1</sup>, Sarah O'Hagan<sup>2</sup>, Jawad Ahmad<sup>1</sup>, Pascal P McKeown<sup>2</sup>, Giles Dobson<sup>3</sup>, Seamus Dolan<sup>1</sup>

Accepted 8 March 2007

**Key Words:** Hyperparathyroidism, Long QT syndrome

## INTRODUCTION.

Primary hyperparathyroidism is a disease characterized by elevated serum calcium and inappropriately raised parathyroid hormone (PTH) levels. Its prevalence is 3/1000 in the general population<sup>1</sup>. Common symptoms include fatigue, thirst, epigastric pain, renal colic and depression. 90% of cases are caused by single parathyroid adenomas and the treatment usually involves surgical excision of the abnormal gland. Inherited long QT syndrome (LQTS) is a disorder characterized by prolonged ventricular repolarisation and a propensity for syncope, polymorphic ventricular tachycardia (torsade de pointes), and sudden death<sup>2</sup>. The disease is now classified as a 'channelopathy', with mutations having been reported in genes encoding cardiac ion channels<sup>3</sup>. We report the case of a 40 year old woman with inherited LQTS who was found to have primary hyperparathyroidism and her subsequent operative management.

## CASE PRESENTATION

A 40 year old woman was diagnosed with LQTS after attending the Cardiology Department of the Royal Victoria Hospital as part of family screening. Several relatives had been identified as carrying a mutation in the KCNQ1 gene. She reported no cardiac symptoms; in particular, she had no past history of syncope. However, she did note the recent onset of fatigue. There was no other past medical history of note and clinical examination was normal. Her resting electrocardiograph (ECG) revealed a QTc interval of 472msec (Fig 1). Ambulatory ECG monitoring and exercise stress testing did not reveal any cardiac arrhythmias and she was commenced prophylactically on low dose beta-blocker to reduce her risk of fatal arrhythmias. Subsequent DNA analysis confirmed that she carried the same KCNQ1 mutation, which had been reported in other family members. Baseline serum electrolytes and thyroid function tests were normal, apart from an elevation in serum calcium of 3.3 mmol/litre [normal range 2.10-2.60 mmol/litre]. Primary hyperparathyroidism was suspected. Serum parathyroid hormone (PTH) was 197pcg/ml (normal range 12-87 pcg/ml) and parathyroid pertechnetate MIBI subtraction scanning showed a large uptake of radionuclide adjacent to the right lobe of the thyroid gland. A diagnosis of primary hyperparathyroidism was made and, in view of the marked persistent elevation of serum calcium, surgical intervention was recommended. Preoperatively, her

levels of magnesium and potassium were optimised and  $\beta$  blockade continued.

Anaesthesia was induced with target-controlled infusion (TCI) of propofol, remifentanyl and vecuronium with full monitoring and an arterial line in place. A very large right inferior parathyroid adenoma was identified and removed (Fig 2).

Postoperatively calcium and magnesium levels and QT interval on the electrocardiogram were measured daily. She was treated with prophylactic oral calcium to prevent a precipitous fall in calcium that may predispose to arrhythmia. Her serum calcium fell to the lower limit of normal and she was discharged home on postoperative day 5 without complication, to continue on oral calcium supplements in the short-term.

## DISCUSSION

Inherited LQTS is characterised by a prolonged QT interval on ECG, and is caused by delayed myocyte repolarisation. It includes a group of disorders, known as channelopathies, which result from mutations in genes encoding cardiac ion channels or ankyrin-B. Patients with this condition are predisposed to ventricular tachyarrhythmias, in particular torsade de pointes, and can present with syncope or sudden death. In certain individuals the syncope may be related to increased emotion or exercise (adrenergic stimulation). To date, over 400 mutations have been reported in eight genes (LQT1-8)<sup>4</sup>. Seven of the eight genes code for ion-channel proteins (potassium / sodium / calcium) and the other gene encodes ankyrin-B, a membrane-anchoring protein associated with Na/K ATPase and the Na/Ca exchanger.

Our patient had a mutation in the KCNQ1 gene (LQT1), the alpha unit of the slowly deactivating delayed rectifier potassium channel. This is one of the most common genes implicated in inherited LQTS<sup>4</sup>. In normal individuals  $\beta$ -adrenoreceptor stimulation reduces the action potential and QT interval; however, with KCNQ1 gene mutations

Departments of Endocrine Surgery<sup>1</sup>, Cardiology<sup>2</sup>, and Anaesthesia<sup>3</sup>, Royal Victoria Hospital, Grosvenor Road, Belfast, BT12 6BA. United Kingdom.

Correspondence to Dr Kennedy

E: rpg.kennedy@btinternet.com

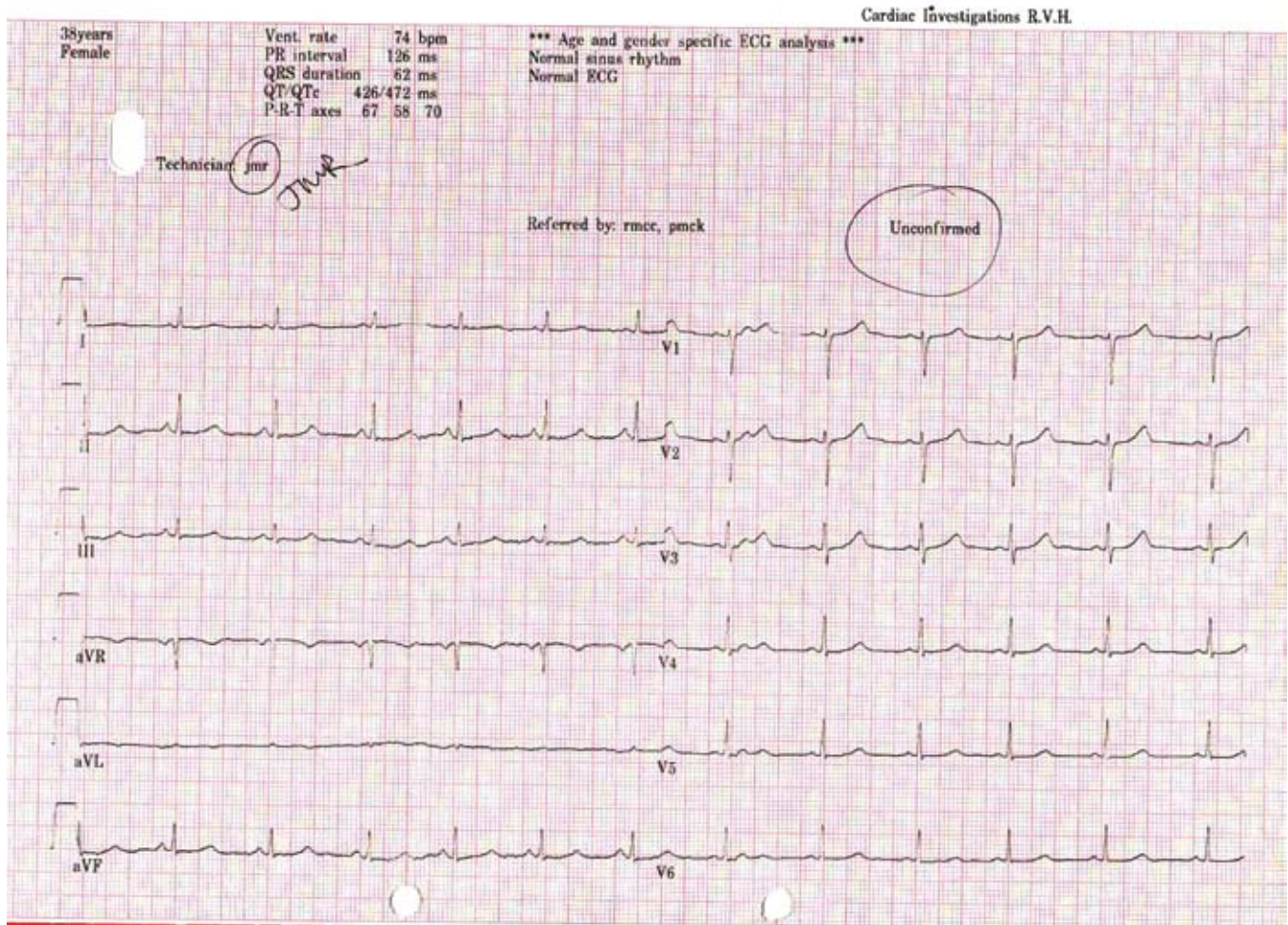


Figure 1. Electrocardiograph showing lengthened QTc interval

the channels do not respond normally, thus predisposing individuals to cardiac arrhythmias. Treatment with  $\beta$ -adrenoreceptor blocking medication can be very effective for these patients<sup>5</sup>. There are several acquired factors that have been shown to cause or worsen QT prolongation including hypomagnesaemia, hypokalaemia, and hypocalcaemia<sup>6</sup>.

Primary hyperparathyroidism is caused by adenomatous (87-90%) or hyperplastic (5-12%) parathyroid gland or glands releasing parathyroid hormone (PTH) autonomously. This causes serum calcium to rise. Following successful surgery PTH levels fall to within the normal range on day one<sup>7</sup>. The lowest serum calcium levels occur around day three when many patients may become temporarily (and asymptotically) hypocalcaemic<sup>8</sup>. Our patient was prophylactically treated with calcium to avoid a sharp drop in her serum calcium.

Anaesthesia in patients with LQTS carries a risk of intra-operative ventricular arrhythmias. Maintenance of normal serum electrolyte levels is important. Alleviating patient anxiety and maintaining preoperative normoxaemia, normocarbida and normoglycaemia all minimize sympathetic activation and may reduce this risk. However the anaesthetic team should be prepared to manage cardiac arrhythmias, including torsade de pointes and ventricular fibrillation.

There are no reported cases in the medical literature of primary hyperparathyroidism and LQTS co-segregating in the same patient. Postoperative hypocalcaemia that may occur following successful surgery and anaesthetic related adrenergic stimulation are risk factors for the development of ventricular arrhythmias in this rare cohort of patients. Careful perioperative  $\beta$  blockade and electrolyte management are essential. Inhalation anaesthetic agents, such as isoflurane and sevoflurane, may prolong the QT interval in unpremedicated healthy humans<sup>9</sup>. However, propofol may have beneficial effects on the QT interval in patients with LQTS and was thus chosen as the anaesthetic agent of choice in this case.

## CONCLUSION

LQTS is a rare condition predisposing to life-threatening ventricular arrhythmias. Its importance lies in the significant morbidity and mortality associated with a failure to recognize and treat it. Our case illustrates the steps that may be taken to minimize this risk in such patients in the perioperative period. These steps include adequate  $\beta$  blockade, avoidance of inhalation anaesthesia, careful attention to electrolyte balance and involvement and co-operation of a multidisciplinary team of specialists.

The authors have no conflict of interest.

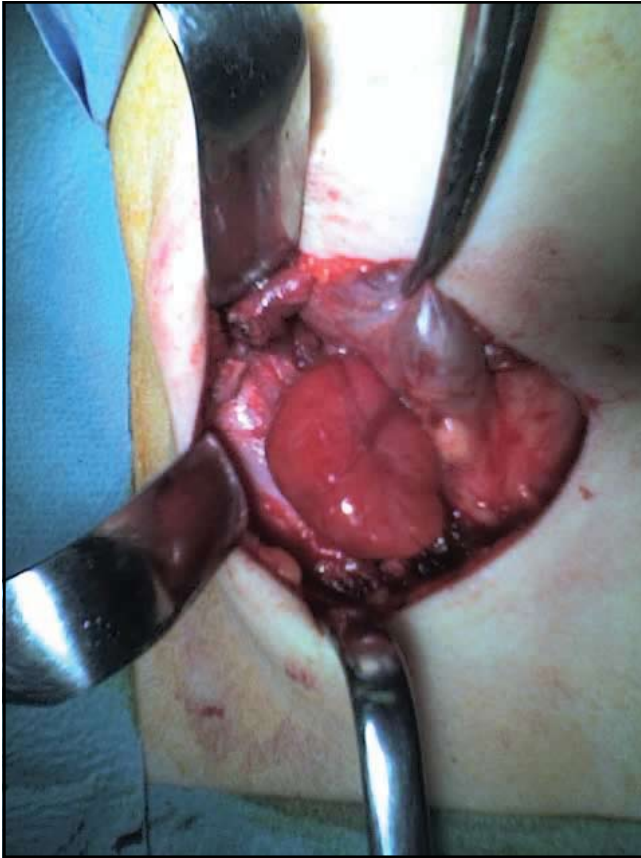

Figure 2. Large right inferior parathyroid adenoma in situ

#### REFERENCES

1. Adami S, Marcocci C, Gatti D. Epidemiology of primary hyperparathyroidism in Europe. *J Bone Miner Res* 2002;**17**(suppl.2):N18-23.
2. Zareba W, Moss AJ, Schwartz PJ, Vincent GM, Robinson JL, Priori SG., et al. Influence of the genotype on the clinical course of the long QT syndrome. International Long-QT Syndrome Registry Research Group *N Engl J Med* 1998;**339**(14):960-5.
3. Keating MT, Sanguinetti MC. Molecular and cellular mechanisms of cardiac arrhythmias. *Cell* 2001;**104**(4):569-80.
4. Modell SM, Lehmann MH. The long QT syndrome family of cardiac ion channelopathies: A HuGE review. *Genet Med* 2006;**8**(3):143-55.
5. Booker PD, Whyte SD, Ladusans EJ. Long QT syndrome and anaesthesia. *B J Anaesth* 2003;**90**(3):349-66.
6. Khan IA. Long QT Syndrome: diagnosis and management. *Am Heart J* 2002;**143**(1):7-14.
7. Denizot A, Pucini M, Chagnaud C, Botti G, Henry JF. Normocalcaemia with elevated parathyroid levels after surgical treatment of primary hyperparathyroidism. *Am J Surg* 2001;**182**(1):15-9.
8. Debruyne F, Delaere P, Ostyn F, van den Bruel A, Bouillon R. Daily follow-up of serum parathyroid hormone and calcium after surgery for primary hyperparathyroidism. *J Otolaryngol* 1999;**28**(6):305-8.
9. Kuenszberg E, Loeckinger A, Kleinsasser A, Lindner KH, Puehringer E, Hoermann C, et al. Sevoflurane progressively prolongs the QT interval in unpremedicated female adults. *Eur J Anaesthesiol* 2000;**17**(11):662-4.