

Technical Note

## Complete mechanical circulatory support using ventricular assist devices for post-cardiotomy biventricular failure.

Nnamdi Nwaejike<sup>1</sup>, Pramod Bonde<sup>2</sup>, Gianfranco Campalani<sup>2</sup>

Accepted 6 September 2007

### ABSTRACT

Cardiopulmonary bypass (CPB) allows operations on the heart in a motionless and bloodless field while reducing cardiac workload and sustaining systemic and coronary perfusion. Failure to wean from CPB remains a significant problem. Results from recent large registry data have shown dramatic improvement in the survival following ventricular assistance for post cardiotomy failure if instituted early. We show how post-cardiotomy heart failure can be successfully treated by proactive use of biventricular assist devices (BIVAD).

### INTRODUCTION

Cardiopulmonary bypass (CPB) allows operations on the heart in a motionless and bloodless field while reducing cardiac workload and sustaining systemic and coronary perfusion. It has gained widespread acceptance but failure to wean from CPB remains a significant problem. Factors determining post-cardiotomy failure include: perioperative ischaemia, complications of PCI, patients presenting with acute coronary syndrome, post-infarct VSD, inadequate myocardial protection, diffuse non-graftable disease, or complications associated with a chronically pressure and volume overloaded ventricle. This can result in a significant amount of hibernating and stunned myocardium.

Post-cardiotomy heart failure can be reversible but carries a high risk of mortality. The initial four decades after the advent of cardiac surgery witnessed a gradual decrease in the incidence of post-cardiotomy failure as a result of improved peri-operative care and better myocardial preservation strategies, however, in the last decade the incidence has gradually started to rise as the case mix for cardiac surgery has become increasingly complex<sup>1</sup>. We have seen a dramatic change in the referral pattern of patients being offered cardiac surgery; many have high risk profiles that would have been denied intervention a decade or two ago.

We present a case of post-cardiotomy failure in a patient with unstable angina with rest pain being treated by biventricular assist devices (BIVAD). This is the first adult case to survive with BIVAD use following cardiac surgery in the province.

### CASE

A 67-year-old man was admitted to the Department of Cardiac Surgery for urgent CABG. Three weeks earlier, he was admitted to the Coronary Care Unit (CCU) with unstable angina and a Non-ST segment myocardial infarction. Angiography revealed triple vessel disease and impaired left

ventricular function (Ejection fraction 18%). His operation was deferred on initial admission due to MRSA grown from the right groin and he continued to experience chest pain on minimal exertion daily, with activity limited to bedside movements only.



Fig 1. Photograph depicting the close up of a Biomedicus (Medtronic Inc) pump with the inlet and outlet connectors. Two pumps were used, one for the right ventricular bypass and one for the left ventricular bypass.

In theatre soon after intubation, he experienced an asystolic arrest and a rapid median sternotomy was performed with CPB. Antegrade cold blood cardioplegia was instituted to arrest and protect the heart and systemic hypothermia to 28°C was used. The left long saphenous vein was used to bypass the Left anterior descending artery (LAD), obtuse marginal artery (OM) and the posterior descending artery (PDA). The patient was re-warmed and an attempt was made to wean off CPB. This was unsuccessful as the heart was barely able to maintain a systolic blood pressure of 60mmHg, with CVP of 20mmHg and wedge pressure 20mmHg despite adequate preload, high inotropic and intra aortic balloon pump (IABP) support. A second attempt was made after giving the heart 20mins on

<sup>1</sup>Department of Vascular and Endovascular Surgery, Barts and The London NHS Trust, The Royal London Hospital, London E1 1BB, UK, and

<sup>2</sup>Department of Cardiac Surgery, Royal Victoria Hospital, Belfast, Northern Ireland, UK

Correspondence to Mr Bonde,  
prambond@hotmail.com

bypass to recover but the left ventricle struggled and the right ventricle showed signs of dilatation and dysfunction. The clinical scenario suggested bi-ventricular failure.

A decision was made to support both ventricles by establishing temporary left and right heart bypass using two Biomedicus (Medtronic Inc; Minneapolis) pumps as Biventricular assist devices (BIVAD). Right heart bypass was achieved by the right atrial two-stage cannula for venous drainage and a 24 French aortic cannula (pulmonary artery cannula) placed in the right ventricular outflow tract and advanced in the main pulmonary artery for return. Left heart bypass was achieved by inserting a 38 French angled anvil cannula (left atrial cannula) through a purse string suture in the right superior pulmonary vein and the inflow cannula was the aortic 24 French cannula initially used for CPB (Fig. 1). With all cannulae in place and secured, heart assist was established and acceptable flow rates in the region of 2.2 lt/min/m<sup>2</sup> achieved (Figs. 2 and 3). All catecholamines except a continuous infusion of nor-epinephrine, milrinone and inhaled nitric oxide were discontinued, the patients' acidosis and lactate levels normalised with 8 hours of BIVAD support.

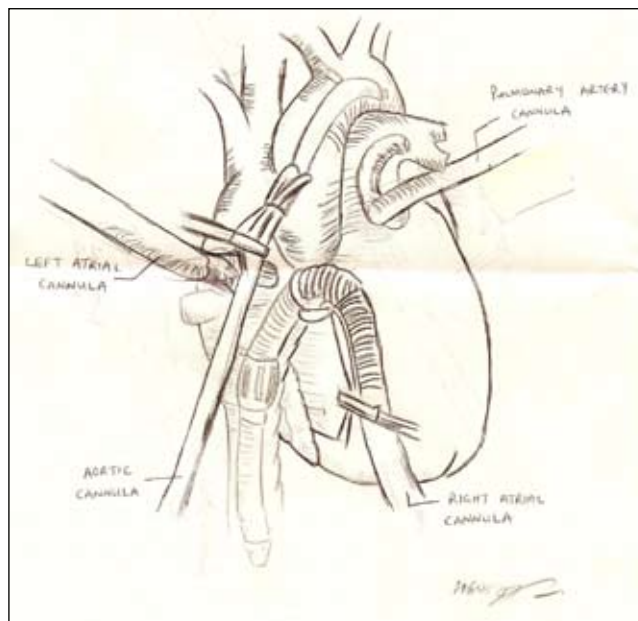


Fig 3. Illustration depicting the insertion of the cannulas for BIVAD.

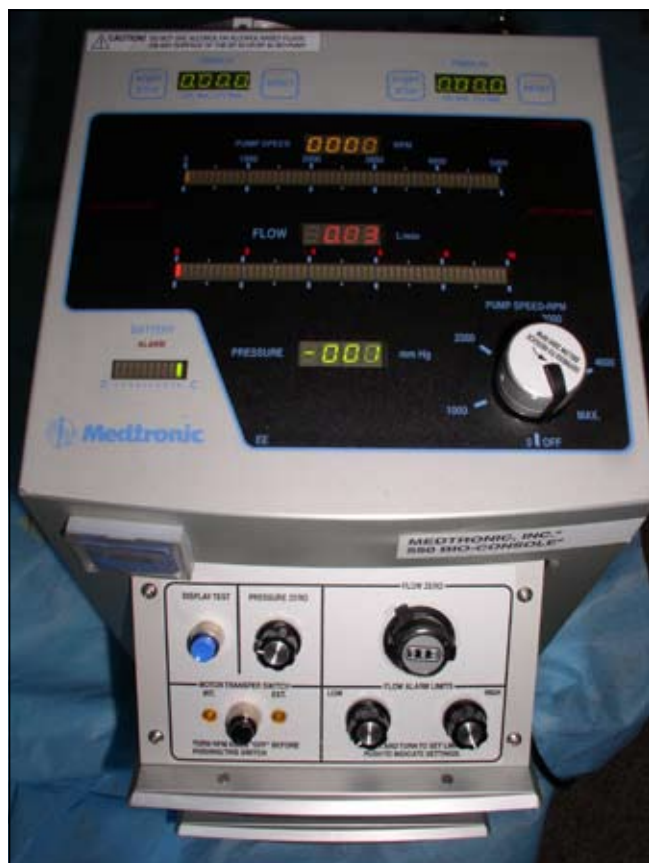

Fig 2. Photograph of the console of the Biomedicus pump (Medtronic Inc), two independent consoles controlled the Biomedicus pumps for flow and revolutions per minute.

The patient developed a coagulopathy due in part to rapid heparinisation and prolonged CPB and required substantial infusions of coagulation products. The chest was left open and packed with sterile gauze and he had repeated re-explorations over the next 24 hours to identify and correct surgical bleeding points as they became apparent.

After 48 hours an improvement in ventricular function was observed on trial of weaning, so BIVAD support was weaned off and removed. The sternum was left open with the skin closed to allow rapid re-exploration if required. By day 4 the sternotomy could be closed without haemodynamic compromise and on day 5, IABP was removed. He made steady improvement and was extubated on day 11 with a minitracheostomy tube placed to aid aspiration of bronchial secretions. He was discharged home on day 43. On review at six weeks, cardiac and respiratory parameters, were satisfactory but an abdominal mass was palpated. He underwent resection for a localised ileal stricture and anastomoses four months from his initial cardiac surgical procedure. At last follow-up he was pain-free and able to walk 2 miles daily.

## DISCUSSION

This case demonstrates a not too infrequent scenario of a significantly stunned myocardium in spite of adequate myocardial revascularisation in a patient with ongoing ischaemia peri-operatively. Currently about 6% of patients develop post-cardiotomy ventricular failure. Phosphodiesterase inhibitors, catecholamines and intra-aortic balloon pump (IABP) are frequently employed for treating post-cardiotomy failure and are successful in the majority of patients. However, 1% of patients undergoing cardiac surgery develop intractable ventricular failure, which is non-responsive to catecholamine and IABP therapy<sup>1</sup>. Traditionally, ventricular assist devices were reserved as a last resort for these types of patients, due to earlier experience of mortality in excess of 75% with the use of assist devices<sup>2,3</sup>.

The Biomedicus pump (Medtronic Inc) used consists of valveless rotator cones that impart a circular motion to incoming blood by viscous drag and constrained vortex principles generating pressure and flow. This assembly is housed in a polycarbonate cone shaped container with inlet and outlet. These pumps are afterload dependent unlike the roller type pump. They can be used to bypass both the

right and left ventricle, are widely available and are easy to operate. They are driven by a magnetic impeller that has no direct contact with the blood within. A separate console allows the operator to control the revolutions and set alarms. Conventional bypass cannulas are used together with bypass tubing to connect the ventricle to the pump outside the body.

A recent comprehensive review of contemporary practice reveals a dramatic improvement in survival following use of ventricular assist devices in patients needing post cardiomy support in several North American centres<sup>4</sup>. This is mainly attributed to earlier recognition and use of assist devices prior to irreversible ventricular failure, improving the overall survival to discharge by ~50%. Early implantation of an assist device capable of supporting adequate flow and allowing the heart to rest may improve results and allow recovery of the stunned myocardium<sup>1,4</sup>. There is an argument for pro-active use of ventricular assist devices early, to gain maximum advantage by allowing the ventricle to recover.

The use of ventricular assist devices is not without technical problems and complications. The *Randomized Evaluation of Mechanical Assistance for the Treatment of Congestive Heart Failure (REMATCH)* trial was designed to compare the results of mechanical assistance versus the medical management for patients suffering from heart failure<sup>5</sup>. This trial results show device infection was 28%; bleeding events were 42%, and device malfunction 35%. This must be balanced with the overwhelming survival benefit of mechanical support. In the LVAD group, the corresponding survival rates were 48% at 12 months and 23% at 24 months, representing a relative risk reduction of death of 48% over the two-year period<sup>5</sup>.

Similar randomised data is lacking in post-cardiotomy failure, due to the ethical issues involved in randomising such patients, but; there is ample data from bridge to recovery and bridge to transplant ventricular assist therapy in the context of post-cardiotomy failure<sup>1,4</sup>.

The centrifugal pumps used in this case are easily available

in most units without dedicated heart failure facilities and are easy to use and maintain. As the patient profiles accepted for coronary revascularisation are undergoing rapid changes towards performing revascularisation procedures in a high-risk population; the use of such devices pro-actively to help the myocardium recover is prudent. Patients can recover to lead a normal life after postcardiotomy heart failure if VAD therapy is instituted early.

#### ACKNOWLEDGEMENTS:

We would like to thank our ICU nursing staff, technicians, anaesthetists and especially our perfusionists, Julie Rea, Nicola McConkey, Carolyn Reid and Ann Panayotou. No conflict of interest declared.

#### REFERENCES

1. Deng MC, Edwards LB, Hertz MI, Rowe AW, Keck BM, Kormos R, *et al.* International Society for Heart and Lung Transplantation. Mechanical circulatory support device database of the International Society for Heart and Lung Transplantation: third annual report--2005. *J Heart Lung Transplant* 2005;**24**(9):1182-7.
2. Noon GP, Lafuente JA, Irwin S: Acute and temporary ventricular support with BioMedicus centrifugal pump. *Ann Thorac Surg* 1999;**68**(2):650-4.
3. Kitamura M, Aomi S, Hachida M, Nishida A, Endo M, Koyanagi H. Current strategy of temporary circulatory support for severe cardiac failure after operation. *Ann Thorac Surg* 1999;**68**(2):662-5.
4. Hernandez AF, Grab JD, Gammie JS, O'Brien SM, Hammill BG, Rogers JG, *et al.* A decade of short-term outcomes in post cardiac surgery ventricular assist device implantation: data from the Society of Thoracic Surgeons' National Cardiac Database. *Circulation* 2007;**116**(6):606-12.
5. Rose EA, Gelijns AC, Moskowitz AJ, Heitjam DF, Stevenson LW, Dembisky W, *et al.* Long-term mechanical left ventricular assistance for end-stage heart failure. *N Engl J Med* 2001;**345**(20):1435-43.