

Paper

# Isolated Mediastinal Adenopathy: The Case for Mediastinoscopy

Terence E McManus<sup>1</sup>, David A Haydock<sup>2</sup>, Peter M Alison<sup>2</sup>, John Kolbe<sup>1,3</sup>

Accepted 3 March 2008

## ABSTRACT

**Background.** We report our experience with mediastinoscopy at Auckland city hospital, a tertiary referral centre. We wished to examine correlations between clinical diagnosis and that made by histological sampling of enlarged mediastinal nodes particularly in patients with isolated mediastinal adenopathy.

**Methods.** We retrospectively reviewed clinical records of all patients who underwent mediastinoscopy in a five year period, mediastinoscopy was performed in the presence of enlarged lymph nodes (short axis > 1cm) found at CT. Mediastinoscopy was indicated for diagnostic staging of mediastinal adenopathy related to a parenchymal lung mass, diagnosis of isolated mediastinal adenopathy and diagnosis of mediastinal adenopathy with other CT findings. Data relating to indication, pre-test diagnosis, node stations sampled, histology, and operative complications were collected.

**Results.** Mediastinoscopy was performed in 137 consecutive patients. Seventy five patients had a lung mass, 47 had isolated mediastinal adenopathy and 15 had other CT findings. One operative complication occurred. In those patients with isolated adenopathy the following diagnoses were reached; sarcoidosis 23, TB 15, lymphoma 4, carcinoma 4, no diagnosis 1. Final diagnosis was significantly associated with patient's ethnicity. There was high sensitivity and specificity on comparison of clinical and histological diagnosis for both TB and sarcoidosis cases.

**Conclusions.** Mediastinoscopy proved to be safe and effective in nodal assessment of the mediastinum. In carefully selected cases procedural morbidity and mortality may be avoided by application of features related to patient's ethnicity and radiological findings.

**Keywords:** Mediastinal lymph nodes, Mediastinoscopy, Computed tomography, Mediastinum

## INTRODUCTION

With the widespread availability of CT scanning, isolated mediastinal adenopathy (IMA), mediastinal adenopathy in the absence of disease elsewhere (figure 1), is increasingly found on scans performed for very different indications and clinicians are faced with the difficult clinical decisions regarding the investigation of a patient with few if any symptoms. Radiological images do not always correlate well with the pathological features of the lesions and consequently imaging diagnostics often fail to provide enough certainty to make therapeutic decisions<sup>1</sup>. CT does not seem to replace mediastinoscopy but rather guides its application. Differential diagnosis includes conditions for which specific therapy is unlikely to be required (sarcoidosis), for which specific therapy is required for cure and/or to prevent future disease (tuberculosis) as well as potentially life-threatening conditions the outcome from which may be considerably influenced by appropriate and timely treatment (lymphoma). The most likely clinical diagnosis of the aetiology of isolated mediastinal adenopathy is based upon patient demographics, symptoms, clinical signs and certain laboratory tests. A histological diagnosis generally requires mediastinoscopy, (which requires general anaesthesia), and an experienced cardio-thoracic surgeon, which are not available in all institutions and is not without risk<sup>2</sup>.

In order to address these issues we undertook a study the overall aim of which was to determine the clinical utility of mediastinoscopy in the diagnosis and management of patients with IMA. Specifically to determine:

- the proportion of patients who have a malignant aetiology for their IMA
- the accuracy of physicians in their pre-operative diagnosis (benign vs. malignant)
- whether there were clinical or radiological features that correlated with a malignant aetiology

## PATIENTS

The institutional review board did not require individual patient consent as this study was retrospective. The clinical records of all patients who underwent mediastinoscopy at

<sup>1</sup>Department of Respiratory Medicine, <sup>2</sup>Department of Cardiothoracic Surgery, and <sup>3</sup> Department of Medicine, Faculty of Medical and Health Sciences, University of Auckland, Auckland 1023, New Zealand

Correspondence to Dr McManus, Department of Respiratory Medicine, Regional Respiratory Centre, Belfast City Hospital, Lisburn Road, Belfast, BT9 7AB. United Kingdom

TerryMcManus@doctors.org.uk

TABLE I  
Patient demographics

Variable	Patient Group		
	Mediastinal Adenopathy & Parenchymal Lung Mass	Isolated Mediastinal Adenopathy (IMA)	Mediastinal Adenopathy & Other CT Findings
Number	75	47	15
Age	61.3 ± 11	44.8 ± 16.4	44.2 ± 15.4
Sex (M / F)	45 / 30	20 / 27	9 / 6
NZ European / Other European	54	22	5
Maori / Pacific Islander	16	6	3
Indian / Asian / African / Chinese	1	18	6
Unknown Ethnicity	4	1	1
Incidental Finding	9	9	0

Auckland City Hospital over a five year period (January 2000 - December 2005) were retrospectively reviewed. Data relating to indication, pre-test clinical diagnosis, histology, length of hospital stay, and operative complications were collected. Mediastinoscopy was performed in the presence of enlarged lymph nodes (short axis > 1cm) found at CT scanning with one or more node stations involved. It is widely accepted that adenopathy of greater than 10mm diameter is indicative of significant enlargement. Mediastinoscopy was performed in 137 patients: in seventy five patients for diagnostic staging of mediastinal adenopathy related to a parenchymal lung mass or known primary lung cancer, in 15 for diagnosis of mediastinal adenopathy with other CT findings and in 47 for IMA. Those with IMA form the basis of this report.

## METHODS

All procedures were performed under general anaesthesia using a single lumen endotracheal tube. Following standard preparation for mediastinoscopy a crease incision was made and dissection was performed deep down to the pre-tracheal fascia. This was then followed by blunt dissection down along the trachea to access the right lower paratracheal and pre-tracheal lymph nodes<sup>3</sup>. Final diagnosis was determined by a combination of histology, other test results, and correlation of all of this information with clinical findings at subsequent follow-up clinic appointments. A diagnosis of tuberculosis (TB) was made if histology showed granulomatous inflammation, and

either *M. tuberculosis* was cultured from the node or other samples, TB Polymerase Chain Reaction tests was positive, acid fast bacilli were seen on histology or the patient had an unequivocal clinical and/or radiologic response to anti-tuberculosis treatment. Alteration of management was defined as a definitive diagnosis which resulted in specific therapy or alternatively avoided further investigative procedures.

## Statistical analysis

Normally distributed data were presented as mean ± standard deviation, whilst non-parametric data were expressed as median and inter quartile ranges. For discrete variables frequencies and percentages were reported and groups compared using the chi squared test. A significance level of

TABLE II  
*Isolated mediastinal adenopathy, correlation of clinical diagnosis with histological diagnosis, sensitivity and specificity*

Clinical Diagnosis	Histological Diagnosis	Inconsistencies	Sensitivity	Specificity
Sarcoidosis	17 of 18 (94%)	TB (1)	74%	96%
TB	13 of 16 (81%)	Sarcoidosis (2), Lymphoma (1)	93%	91%
Lymphoma	3 of 7(43%)	SCLC (1), NSCLC (1), Sarcoidosis (1), No diagnosis (1)	75%	91%
Carcinoma	2 of 5 (40%)	Sarcoidosis (2), no diagnosis (1)	50%	95%
Unknown	-	Sarcoidosis (1)	-	-

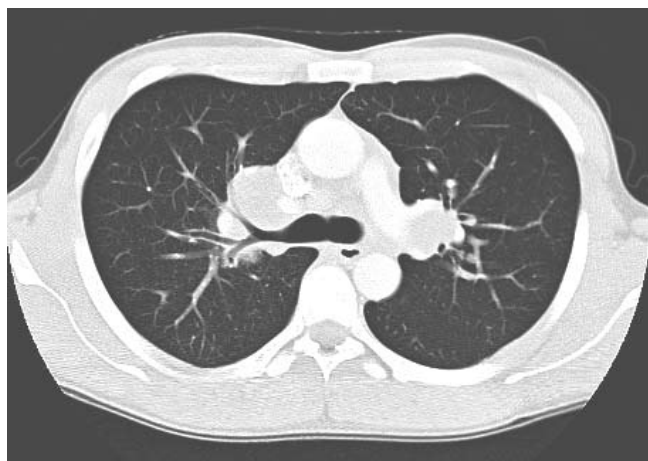


Fig 1. CT chest demonstrating bilateral hilar adenopathy.

5% was chosen. Statistical analysis was carried out using SPSS (Chicago, IL) version 10.0.

## RESULTS

Mediastinoscopy was performed in 137 consecutive patients. Patient demographics are shown in table I; those patients in the IMA group were younger, more likely to be non-European and the radiologic abnormality more likely to have been an incidental finding. Median length of stay was 2 days in all groups. In all cases but one, lymph node tissue was obtained. Of the 75 patients with a lung mass, 52 were known to have a malignant underlying process (51 NSCLC, 1 metastatic germ cell tumour). Following mediastinoscopy 18 were found to have non small cell lung cancer, other diagnosis's made on nodal biopsy included TB (1), lymphoma (1) and SCLC (1). In 2 cases no final diagnosis was reached following mediastinoscopy.

### Isolated Mediastinal Adenopathy

The pre-operative clinical diagnoses and the final diagnoses are shown in table II. One patient who had a pre-operative diagnosis of a benign condition (tuberculosis) was found to have malignancy (lymphoma). Five of the 12 who were suspected of having a malignant aetiology had a final diagnosis of a benign condition (sarcoidosis). Of the nine cases of IMA which were picked up as incidental findings on chest X-ray's which were carried out for other illness or for employment / immigration purposes, seven were found to have tuberculosis, 1 sarcoidosis and one lung cancer (non small cell lung cancer). In almost all of these IMA cases mediastinoscopy was followed by an alteration in management (98%). Subsequent analysis of clinical diagnosis and the definitive histological findings demonstrated high specificity for all diagnoses. Following analysis of symptom correlation with final diagnosis, a diagnosis of TB was negatively associated with a history of chest pain ( $p < 0.05$ ). No other associations were found.

### Ethnicity and Final Diagnosis

Patient's ethnicity was correlated with respect to their final diagnosis. New Zealand (NZ) European ethnicity was associated with a final diagnosis of sarcoidosis and malignancy ( $p < 0.05$ ) but negatively correlated with a diagnosis of TB ( $p < 0.0005$ ). The converse was found in

immigrant populations (Indian, Asian, Chinese, African), with a positive association seen for TB ( $p < 0.0005$ ) and a negative association for sarcoidosis ( $p < 0.005$ ) or malignancy ( $p < 0.05$ ).

### Adenopathy Location and Final Diagnosis

Analysis of the location of enlarged nodes and the final diagnosis was made. Positive associations were seen between mediastinal adenopathy and diagnoses of sarcoidosis or lymphoma ( $p < 0.05$ ). Lymphoma was also associated with paratracheal adenopathy ( $p = 0.05$ ). An incidental finding of interest was that all cases of aortopulmonary window adenopathy were found to be associated with lung carcinoma in those patients who had a parenchymal lung mass ( $p < 0.05$ ). Also all patients who had mediastinal adenopathy in association with pulmonary nodules were found to have sarcoidosis.

## DISCUSSION

Although the clinical pre-operative diagnosis was able to fairly reliably distinguish between benign and malignant aetiologies (sensitivity = 87 – 88%, specificity = 78 – 87%), clinical assessment was less reliable at distinguishing sarcoidosis from tuberculosis. Therefore in both benign and malignant conditions a precise histological diagnosis is required and thus a strong case can be made for mediastinoscopy in all cases of IMA.

Previous studies investigating the role of mediastinoscopy in the diagnosis of isolated mediastinal adenopathies have also shown a high sensitivity<sup>4</sup>. The benefits of an accurate diagnosis obtained by mediastinoscopy need to be balanced against the risks of the procedure. In the IMA group, none of the patients sustained a significant adverse outcome, although one of the other 90 patients who underwent mediastinoscopy during the period of this review developed life-threatening haemorrhage and required repair of an innominate artery rupture under cardio-pulmonary by-pass. The relatively low rates of complication (compared with published mortality rates of 0% - 0.2% and morbidity rates of 0.6% - 2.7%<sup>4-8</sup>) is likely due to the fact that all procedures were under-taken in a dedicated cardio-thoracic service. One large series recorded 1% of patients experiencing complications consisting of haemorrhage, vocal cord dysfunction, tracheal injury and pneumothorax<sup>9</sup>.

Median duration of hospital stay at two days was similar to that reported in other studies<sup>7</sup>. A specific diagnosis with a high likelihood of altering treatment was obtained at low risk to the patient. This is consistent with a previous study examining the risk / benefits of mediastinoscopy in the investigation of asymptomatic bilateral hilar adenopathy which found that the benefits of diagnosing persons with conditions other than sarcoidosis would be offset by procedural mortality with significant cost implications<sup>10</sup>.

There was high sensitivity and specificity for the clinical diagnosis of sarcoidosis and TB when comparison was made to histological diagnosis following mediastinoscopy. However the significance of misdiagnosing a potential case of TB as sarcoidosis infers that any cases with suspicious presentation (detection on immigration CXR) and risk factors (from a high prevalence TB region) or the presence of atypical CT findings

(infiltrates) should proceed to mediastinoscopy to obtain a diagnosis. These findings are reflected in previous publications and the point made that diagnosis can even be difficult when tissue is obtained<sup>11</sup>. Whilst mediastinal adenopathy in the absence of pulmonary infiltrates is an unusual but recognized presentation for TB the diagnosis can nevertheless be difficult<sup>12</sup>. Two cases were initially diagnosed as sarcoidosis on the basis of histology but were subsequently found to be due to TB. Both cases were non-European (Indian), in one *M. tuberculosis* was cultured from bronchial washings (presentation with atypical chest pain) and in the other there was a positive mantoux (18mm), an interval increase (x3) in node size and a clear radiological response to anti-tuberculous therapy (detected on a pre-employment CXR).

Although mediastinoscopy is a safe and accurate procedure in patients with asymptomatic stage I sarcoidosis, clinical and imaging monitoring may be more appropriate<sup>13</sup>. Alternate means of obtaining a histological diagnosis of sarcoidosis needs to be considered. Previous authors have suggested that in up to approximately 50% of cases a diagnosis of sarcoidosis can be obtained by conjunctival biopsy, avoiding the more expensive and invasive procedure of mediastinoscopy<sup>14</sup>. The authors advise that multiple tissue specimens should be examined as granulomas may be randomly distributed, and also bilateral biopsies can increase the diagnostic yield.

Similar to the results of a previous study, the commonest diagnosis of IMA was sarcoidosis<sup>14</sup>. The cause of IMA may vary markedly in different populations: other studies having identified lymphoma as the major pathological entity<sup>15</sup>. This may be related to selection bias or actual prevalence differences in different populations. Although the proportion of the major diagnoses may differ, this does not negate the findings of this study nor the conclusion that an accurate diagnosis is required in all cases.

Areas of deficiency of this study are that it was retrospective in nature thus symptom recording and clinical diagnosis were influenced by each individual physicians approach. Also the study numbers are relatively small when used for subgroup analysis. These findings should ideally be confirmed in a prospective study with data acquisition as part of set criteria. However, despite these factors the findings of this study are applicable to European populations in which the prevalence of TB is low but which do have a significant immigrant population from areas of high TB prevalence.

While mediastinoscopy is a safe and accurate procedure other potential methods of obtaining histological specimens of enlarged paratracheal lymphadenopathy include the use of CT guided bronchoscopic transtracheal needle biopsy. Sufficient material for diagnostic purposes can be obtained in the majority of cases and this technique represents an effective, less invasive methodology with a low complication rate, there was however a relatively high false negative rate of 50%<sup>16</sup>. CT-guided transthoracic fine needle aspiration with or without core biopsy accesses many mediastinal nodal stations with a high diagnostic yield albeit in patients with lung cancer rather than IMA<sup>17</sup>. Endoscopic ultrasound guided fine needle aspiration has been shown to be a safe, minimally invasive procedure for the diagnostic approach to mediastinal lymphadenopathy<sup>18</sup>. When used in combination with transbronchial needle aspiration the diagnostic yield

approaches that of mediastinoscopy<sup>18</sup>. This procedure has also been applied to patients with suspected sarcoidosis resulting in a diagnosis in 82% of cases with no complications<sup>19</sup>. This technique is complementary to transbronchial needle aspiration and mediastinoscopy as it allows sampling of nodal stations not accessible by the other two procedures<sup>20</sup>. Positron emission tomography (PET) scanning when applied to the examination of mediastinal adenopathy is usually in the setting of staging non small cell lung cancer. PET has been shown to have higher sensitivity specificity and accuracy when compared to CT in staging mediastinal nodes<sup>21</sup>. Studies investigating the use of PET-CT compared to CT alone and videomediastinoscopy in patients with mediastinal masses demonstrated that whilst videomediastinoscopy remains the gold standard PET-CT is of value when differentiating benign from malignant lesions<sup>22</sup>.

Mediastinoscopy is the most sensitive and specific diagnostic tool when presented with mediastinal adenopathy. There are relatively few complications and lymph node tissue was obtainable in nearly every case. Use of this procedure resulted in histological diagnosis and an alteration of management in most cases. In conclusion, patients with isolated mediastinal adenopathy who are of European ethnicity invariably have sarcoidosis, in these cases it is reasonable to observe patients only. Patients who are immigrants from regions of high TB prevalence and who have evidence of mediastinal adenopathy which is incidentally identified on chest imaging for immigration purposes usually have underlying TB. Thus in carefully selected cases procedural morbidity and mortality may be avoided by application of features related to patient's ethnicity and radiological findings.

Acknowledgements: Kirstin Wilson, Decision Support, Level 3, Building 14, Greenlane Hospital Site, Auckland. Raka Tandon, Surgical booking administrator, Department of Cardiothoracic Surgery, Auckland City Hospital.

The authors have no conflict of interest

## REFERENCES

1. Rami Porta R. Surgical exploration of the mediastinum by mediastinoscopy, parasternal mediastinotomy and re-mediastinoscopy: indications, technique and complications. *Ann Ital Chir* 1999;**70**(6):867-72.
2. Sarrazin R, Dyon JF. [Mediastinoscopy]. *Rev Mal Respir* 1992;**9**(1):99-110. [French]
3. Kirschner PA. Cervical mediastinoscopy. *Chest Surg Clin N Am* 1996;**6**(1):1-20.
4. Porte H, Roumilhac D, Eraldi L, Cordonnier C, Puech P, Wurtz A. The role of mediastinoscopy in the diagnosis of mediastinal lymphadenopathy. *Eur J Cardiothorac Surg* 1998;**13**(2):196-9.
5. Hammoud ZT, Anderson RC, Meyers BF, Guthrie TJ, Roper CL, Cooper JD et al. The current role of mediastinoscopy in the evaluation of thoracic disease. *J Thorac Cardiovasc Surg* 1999;**118**(5):894-9.
6. Pattison CW, Westaby S, Wetter A, Townsend ER. Mediastinoscopy in the investigation of primary mediastinal lymphadenopathy. *Scand J Thorac Cardiovasc Surg* 1989;**23**(2):177-9.
7. Rodriguez P, Santana N, Gamez P, Rodriguez dC, Varela dU, Freixinet J. [Mediastinoscopy in the diagnosis of mediastinal disease. An analysis of 181 explorations]. *Arch Bronconeumol* 2003;**39**(1):29-34.
8. Hajjar W, Elmedany Y, Bamousa A, Saladein M, Ashour M, Fouda M et al. Diagnostic yield of mediastinal exploration. *Med Princ Pract* 2002;**11**(4):210-3.

9. Lemaire A, Nikolic I, Petersen T, Haney JC, Toloza EM, Harpole DH, Jr. *et al.* Nine-year single center experience with cervical mediastinoscopy: complications and false negative rate. *Ann Thorac Surg* 2006;**82**(4):1185-9.
10. Reich JM, Brouns MC, O'Connor EA, Edwards MJ. Mediastinoscopy in patients with presumptive stage I sarcoidosis: a risk/benefit, cost/benefit analysis. *Chest* 1998;**113**(1):147-53.
11. Liu X, Zhang D, Lin D, Zhao J, Wang L. [The role of mediastinoscopy for the diagnosis of mediastinal tuberculous lymphadenopathy and sarcoidosis]. *Zhonghua Jie He He Hu Xi Za Zhi* 1999;**22**(3):156-8. [Chinese]
12. Hainaut P, Monthe A, Lesage V, Weynand B. Tuberculous mediastinal lymphadenopathy. *Acta Clin Belg* 1998;**53**(2):114-6.
13. Nuria A, Reis A, Bernardo J, Antunes P, Segorbe A, Eugenio L *et al.* [Mediastinoscopy in the diagnose of sarcoidosis]. *Rev Port Pneumol* 2003;**9**(5 Suppl):36-37. [Portuguese]
14. Leavitt JA, Campbell RJ. Cost-effectiveness in the diagnosis of sarcoidosis: the conjunctival biopsy. *Eye* 1998; **12**(6):959-62.
15. Massone PP, Lequaglie C, Magnani B, Ferro F, Cataldo I. The real impact and usefulness of video-assisted thoracoscopic surgery in the diagnosis and therapy of clinical lymphadenopathies of the mediastinum. *Ann Surg Oncol* 2003;**10**(10):1197-202.
16. Ewert R, Dorffel W, Rogalla P, Mutze S. Computed tomography-guided transtracheal needle aspiration of paratracheal lymphadenopathy in endoscopically normal patients. *Invest Radiol* 1997;**32**(11):667-70.
17. Zwischenberger JB, Savage C, Alpard SK, Anderson CM, Marroquin S, Goodacre BW. Mediastinal transthoracic needle and core lymph node biopsy: should it replace mediastinoscopy? *Chest* 2002;**121**(4):1165-70.
18. Khoo KL, Ho KY, Nilsson B, Lim TK. EUS-guided FNA immediately after unrevealing transbronchial needle aspiration in the evaluation of mediastinal lymphadenopathy: a prospective study. *Gastrointest Endosc* 2006;**63**(2):215-20.
19. Annema JT, Veselic M, Rabe KF. Endoscopic ultrasound-guided fine-needle aspiration for the diagnosis of sarcoidosis. *Eur Respir J* 2005; **25**(3):405-9.
20. Herth FJ, Lunn W, Eberhardt R, Becker HD, Ernst A. Transbronchial versus transesophageal ultrasound-guided aspiration of enlarged mediastinal lymph nodes. *Am J Respir Crit Care Med* 2005;**171**(10):1164-7.
21. Gupta NC, Graeber GM, Bishop HA. Comparative efficacy of positron emission tomography with fluorodeoxyglucose in evaluation of small (<1 cm), intermediate (1 to 3 cm), and large (>3 cm) lymph node lesions. *Chest* 2000;**117**(3):773-778.
22. Liu Q, Peng ZM, Liu QW, Yao SZ, Zhang L, Meng L *et al.* The role of 11C-choline positron emission tomography-computed tomography and videomediastinoscopy in the evaluation of diseases of middle mediastinum. *Chin Med J (Engl)* 2006;**119**(8):634-9.