

Paper

## Foreign Body Ingestion in Prisoners – The Belfast Experience

May Bisharat<sup>1</sup>, Mark E O'Donnell<sup>1,3</sup>, Niall Gibson<sup>1</sup>, Michael Mitchell<sup>2</sup>, Sigi R Refsum<sup>1</sup>, P Declan Carey<sup>1</sup>, Roy AJ Spence<sup>1,3</sup>, Jack Lee<sup>1</sup>

Accepted 1 November 2007

**Keywords:** Gastrointestinal, Foreign Body, Ingestion, Prison.

Winner of the best clinical paper, Ulster Society for Gastroenterology Spring Meeting, Belfast April 2007.

### SUMMARY:

Deliberate ingestion of foreign bodies is common amongst prison inmates. The motives behind the ingestion are variable. As the only designated hospital in Northern Ireland treating acute surgical pathologies in the prison population, we reviewed our experience of foreign body ingestion between March 1998 and June 2007. Types of foreign objects, symptomatology, haematological analyses, radiological findings, operative intervention and complications were retrieved from case notes. A literature search was performed using Medline to correlate this clinical data with published evidence to produce therapeutic guidelines to assist the surgical multi-disciplinary team.

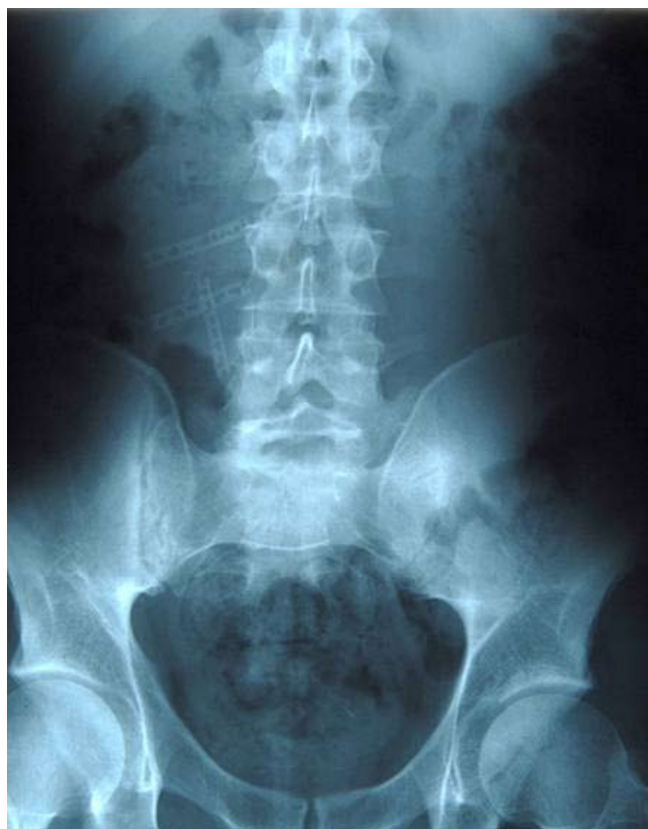

Fig 1. Razor blades in the small bowel.

Eleven prisoners presented with foreign body ingestion over the study period (M=8 and F=3, mean age: 28.1 years, range 21-48). Mean follow-up was 597 days (range 335-3325 days). Although the literature states that most foreign bodies usually pass spontaneously without the need for intervention, this study demonstrates a higher intervention rate of 36% within the Northern Irish prison population in comparison with other prisoners.

### INTRODUCTION

Ingestion of foreign bodies is a common clinical problem. Difficulties can often occur in both diagnostic and management protocols. Approximately 80% of cases occur in the paediatric population with ingestion frequently occurring accidentally<sup>1</sup>. In adults, the unintentional swallowing of objects occurs mainly in the elderly population and those patients with learning disabilities and alcohol dependence, whereas intentional episodes occur commonly in psychiatric patients and prisoners<sup>2</sup>. In the latter group razor blades, batteries and other sharp metallic items are most commonly encountered<sup>1</sup>.

In the general population, 80-90% of foreign bodies will pass spontaneously<sup>3</sup>. However, endoscopic intervention is required in 10-20% of patients with less than 1% of patients requiring surgery<sup>3</sup>. The prison population is a unique environment with different emotional and physical constraints where both the nature and motives behind ingestion are ambiguous with further difficulties encountered in the diagnosis and management of such patients.

### OBJECTIVE

To perform a clinical epidemiological review of all patients from the prison population in Belfast who presented to the Belfast City Hospital for management of ingested foreign bodies and to correlate these clinical data with published evidence to produce therapeutic guidelines to assist the surgical multi-disciplinary team.

Departments of General Surgery<sup>1</sup> and Gastroenterology<sup>2</sup> Belfast City Hospital, Lisburn Road, Belfast; and Faculty of Life and Health Sciences, University of Ulster<sup>3</sup>, United Kingdom. Presented at the Association of Surgeons of Great Britain and Ireland - Annual Meeting, Bournemouth, UK - 14th to 16th May 2008.

Correspondence to Mark E O'Donnell, 42 Woodrow Gardens, Saintfield BT24 7WG. United Kingdom.

modonnell904@hotmail.com

TABLE I

Clinical data for all 11 patients

(RIF=Right iliac fossa, RUQ=Right upper quadrant, SB=Small bowel, SBO=Small bowel obstruction).

No	Age	Sex	Type of FOREIGN BODY	Intentional	Repeated ingestion	AXR	CT Scan	Endoscopy: attempted retrieval	Surgery	Hospital Stay (days)	Outcome
1	29	M	Razors	Yes		3 Razors in SB		No	No	1	Alive
2	23	M	Razors	Yes		1 Razor in SB		No	No	1	Alive
3	31	M	20p coin	Yes		20p coin in RIF, SBO	Complete SBO	Yes – colonoscopy: failed	Laparotomy: Resection of terminal ileum and Right hemicolectomy	6	Alive : diagnosed with Crohn's disease
4	25	F	Razors	Yes		Razor in RUQ		No	No	1	Alive
5	26	M	Razors	Yes		1 Razor in SB		No	No	1	Alive
6	21	M	Batteries	Yes	Yes – Razors	3 Batteries in SB		No	No	1	Alive
7	23	M	Razors	Yes		5 Razors in SB, 1 in rectum		No	No	1	Alive
8	24	M	Razors	Yes	Yes – Razors and Metallic Rod	2 Razors in SB and rectum		No	No	1	Alive
9	37	F	Batteries	Yes	Yes – Batteries	6 Batteries in SB, SBO		No	Laparotomy: enterotomy	6	Alive
10	22	M	Batteries	Yes	Yes - Batteries	2 Batteries in SB, SBO		No	Laparotomy : enterotomy	8	Alive
11	48	F	Watch	Yes		Watch in RIF		Yes – successful extraction	No	4	Alive

## METHODS

A nine-year retrospective review of all prisoners presenting with foreign body ingestion to the Belfast City Hospital Surgical Unit was completed. Clinical records were then reviewed for data regarding patient demographics, type of foreign body ingested, intention of ingestion, clinical presentation, past medical and social history, haematological analyses, radiological findings, management details including the need for operative intervention and complications. A further assessment of any previous admissions with similar complaints was completed from review of the hospital patient administration system. Follow up was completed for all patients by the prison medical teams with specialist review in the Belfast City Hospital as required.

## RESULTS

**Demographics:** Eleven prisoners (8 males, 3 females) presented with gastrointestinal foreign bodies over the study period. Mean age was 28.1 years (range 21 - 48). Mean admission duration was 2.3 days. Ingested foreign bodies identified included razor blades (n=6), batteries (n = 3), a

20-pence coin (n = 1) and a wrist watch (n = 1), (Figs 1 - 3). Presenting symptoms included reduced appetite (n = 4), vomiting (n = 8), abdominal pain (n = 8) and constipation (n = 5). None of the patients had a significant gastrointestinal past medical history. Most smoked tobacco (n = 8) and consumed alcohol (n = 6) on a regular basis. See Table I for clinical data for all 11 patients.

**Investigations:** Haematological analyses were normal on admission except for a mean raised C-reactive protein of 47.2 mg/l (range 2 - 221). A plain abdominal X-ray confirmed the presence of a metallic foreign body in all patients. An erect chest X-ray was normal in all patients. Computerised Tomography (CT) imaging was required in patient 3, which confirmed small bowel obstruction secondary to an impacted 20-pence coin at the terminal ileum.

**Management:** Seven patients were managed conservatively. Patients 3 and 11 underwent attempted endoscopic retrieval of the foreign body. Patient 3 admitted to swallowing a 20-pence coin. The coin had impacted in the terminal ileum and attempts at endoscopic retrieval were unsuccessful. He proceeded to laparotomy where the terminal ileum and right

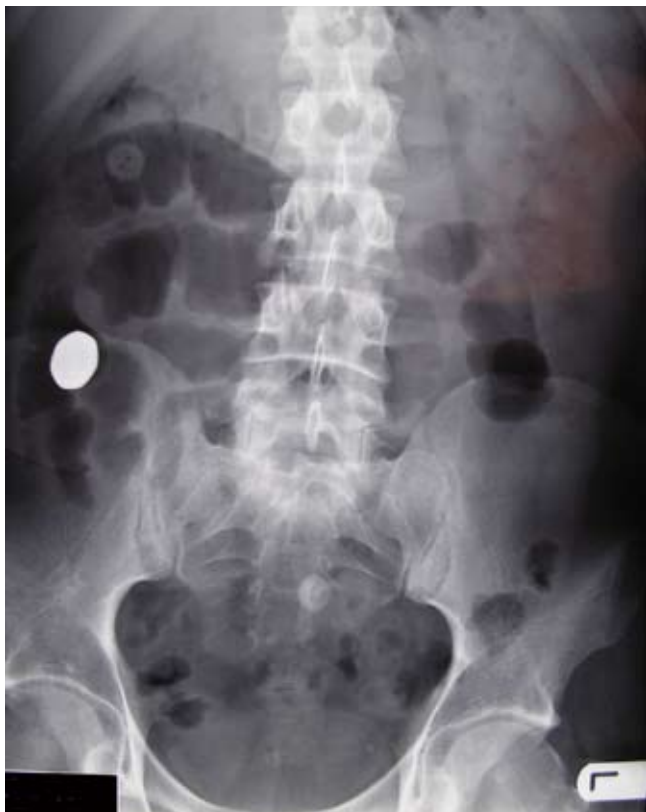

Fig 2. 20-pence coin in the right iliac fossa. Dilated loops of small bowel proximal to coin. Reproduced with permission from the Irish Journal of Medical Science - Reference 4

colon were resected with a primary anastomosis performed. Histopathological analysis revealed Crohn's Disease with stricturing distal to the impacted 20-pence coin<sup>4</sup>. Patient 11 was admitted after intentionally swallowing a wrist-watch 6-weeks prior to presentation. Endoscopic retrieval from the ileo-caecal junction was successful (Figs 3, 4). Two further patients (9 & 10) required operative intervention for continuing obstructive symptomatology. An enterotomy was performed with extraction of the metallic foreign body followed by primary closure in both instances.

**Outcome:** Mean follow-up was 597 days (range 335-3325 days) and was complete for all patients. There were no significant post-operative or long-term complications. All (n = 11) cases of foreign body ingestion were intentional. Almost half of the patients (n = 4) repeated the ingestion of foreign objects (Fig 5).

#### DISCUSSION:

Ingestion of metallic foreign bodies remains a common problem amongst prison inmates. Swallowing multiple objects at once or repeating the ingestion is a frequent occurrence<sup>2</sup>. The motives behind the ingestions vary. Underlying psychiatric conditions such as schizophrenia, depression, self-mutilation, masochism and suicidal tendencies, attempts to escape incarceration by transfer to a hospital or psychiatric unit, genuine accidental ingestions and attempts at drug trafficking are common motives<sup>1,3,5-6</sup>. Blaho *et al* demonstrated a very high incidence of foreign body ingestion from 2 different prison populations during a 5-week study period where 14 ingestions were noted in 8 male prisoners<sup>6</sup>.

The foreign bodies ingested and the methods of ingestion were similar. Communication between the inmates of both prisons was well established<sup>6</sup>. This study suggested imitative behaviour as an underlying cause.

There is no published epidemiological data describing the true prevalence of foreign body ingestion in the prison population. From review of published case series, patients affected range from 22 to 167 cases in the United States series to 261 cases from larger European studies<sup>3, 7-8</sup>.

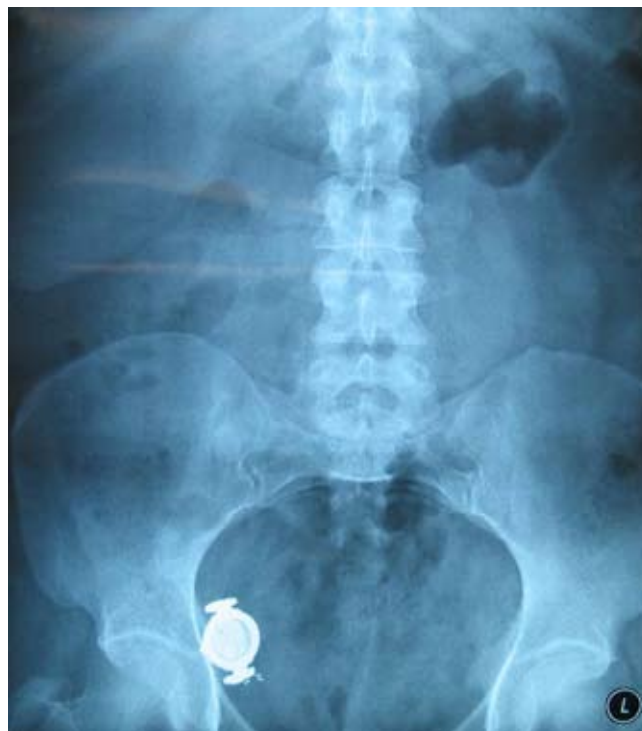

Fig 3. Wrist-watch in right iliac fossa. Failure to progress beyond terminal ileum.

The majority of foreign bodies that reach the gastrointestinal tract will pass spontaneously. Foreign body impaction may occur at areas of anatomical narrowing (the cricopharynx, the lower oesophageal sphincter, the pylorus, the ileocaecal valve and the anus), physiological angulation (the curvature of the duodenum) or areas of pathological strictures (terminal ileum in Crohn's disease)<sup>1,2,4,6,9</sup>. The most common sites for perforation are the lower oesophagus and terminal ileum<sup>2,9</sup>. Bleeding occurs when injury to the gastrointestinal mucosa occurs.<sup>5</sup> Generally, foreign bodies greater than 2-2.5 cm in size will not enter the pyloric canal and those exceeding 6-10 cm in length will not progress through the curvature of the duodenum<sup>1-2,10</sup>.

Treatment depends on the patient's age and symptomatology, nature and type of ingested foreign body and the anatomical location especially if impacted. Foreign bodies may be managed conservatively or therapeutically with endoscopic, laparoscopic or open surgical methodologies. Blunt objects such as coins can impact in the oesophagus resulting in partial or complete obstruction. Endoscopic retrieval should be attempted in all instances, as prolonged lodgment can lead to pressure necrosis, perforation or fistula formation<sup>1-2</sup>. A prospective *in vivo* study by Feigel *et al* demonstrated that a

retrieval net was superior to the basket or forceps technique<sup>11</sup>. If the blunt object has passed in to the stomach and is less than 2cm in diameter, a conservative outpatient management protocol with weekly radiographs should be adopted. If the blunt object remains in the stomach, it has been recommended to delay endoscopic retrieval for 1-2 months to facilitate any opportunity for spontaneous passage<sup>2,5,11,12</sup>. Blaho *et al* also recommend a 3–4 week waiting period to allow passage before attempts at endoscopic retrieval are made<sup>5</sup>. Zuloaga *et al* suggest a two month waiting period<sup>12</sup>. One of the patients in our study presented with a five week history of colicky right iliac fossa pain. The abdominal X-ray on presentation revealed a wrist-watch in the right iliac fossa suggestive of probable impaction at the terminal ileum (Fig 3). Repeat X-rays showed



Fig 4. Endoscopic retrieval of wrist-watch was successful. The watch was still functioning.

failure of progression of the object. Colonoscopic retrieval of the wrist-watch was successful on day-3 post-admission (Fig 4).

Endoscopic retrieval of sharp objects, such as razor blades, straightened paperclips and needles that are lodged in the oesophagus should be performed urgently<sup>1,2</sup>. If the object progresses into the stomach or duodenum, immediate attempts at endoscopic retrieval should be undertaken, as the risk of perforation at the ileocaecal valve is approximately 35%<sup>1,2,9</sup>. If the sharp object has passed beyond the duodenum, the patient should be monitored with daily radiographs and remain under strict observation. Surgical intervention may be required if a sharp object fails to progress radiologically after 72-hours. Emergency laparotomy is required if the patient develops acute clinical signs<sup>1,2</sup>. All six patients that swallowed razor blades in our study presented after the blades had passed into the small bowel. None of them developed symptoms of obstruction or perforation and consequently were successfully managed conservatively.

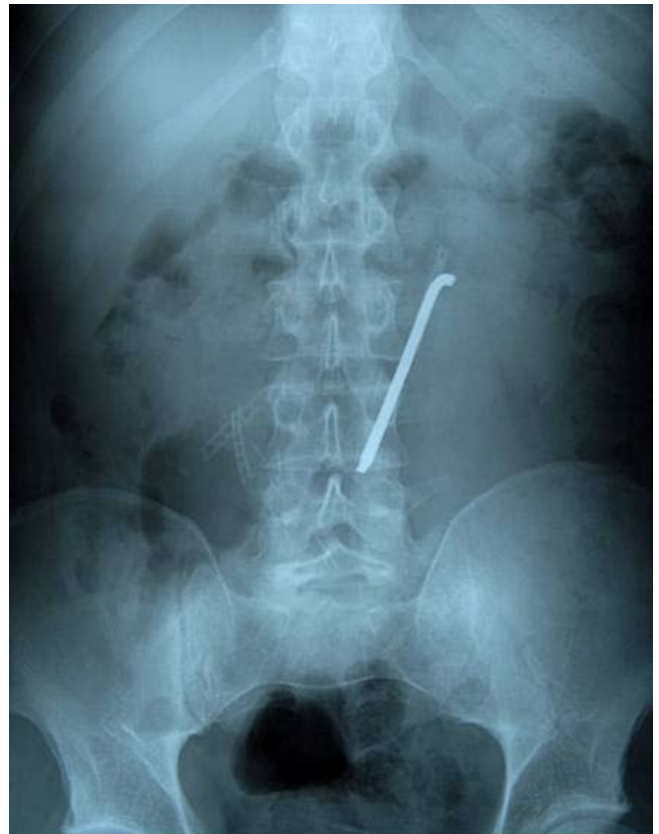


Fig 5. Re-ingestion of metallic rod combined with previous ingestion of razor blades as shown in Figure 1.

Batteries (disc or button) require urgent endoscopic retrieval if lodged in the oesophagus due to the possible risk of chemical burns, electrical discharge and liquefaction necrosis which can lead to subsequent perforation<sup>1,2</sup>. Once the battery has passed into the stomach, retrieval is only indicated if it remains in the stomach beyond 48 hours, or if it is a larger battery measuring more than 2cm in diameter<sup>2</sup>. Once beyond the duodeno-jejunal flexure, 85.4% are passed within 72-hours<sup>13</sup>. A follow-up radiograph twice per week is sufficient<sup>2</sup>. Laxatives and anti acids have no proven benefit in management, however gastric lavage has been described to facilitate removal<sup>14</sup>. Our study showed that 67% of patients that swallowed batteries developed small bowel obstruction requiring a laparotomy with enterotomy. Murshid *et al* also describe the successful laparoscopic extraction of a sewing needle from the terminal ileum of a 17-year-old female after failure of the endoscopic approach<sup>9</sup>. Packages of narcotics should not be removed endoscopically as the risk of rupture and leak of the toxic substance is high<sup>1,2</sup>. Surgical intervention is reserved for those cases where signs of obstruction or leakage of substance occurs<sup>2</sup>. A management protocol is outlined in Table II.

Many prisoners who deliberately swallow foreign bodies ingest multiple objects or repeat the ingestion in a further episode<sup>5,7</sup>. Weiland *et al* demonstrated that amongst 22 male prisoners there were 75 separate hospitalisations, with a total of 256 objects swallowed<sup>7</sup>. In our study 36% of prisoners repeated the ingestion. Patient 8 was managed conservatively following ingestion of razor blades. He represented a few weeks later with ingestion of further razor blades and a metallic rod (Fig 5).

TABLE II

Recommended management protocol for ingested foreign bodies.

Type of Object	Site of Object	Management Protocol
Batteries	Oesophagus	Urgent endoscopic retrieval
	Stomach and Duodenum	If > 48 hrs → endoscopic retrieval
		If > 2 cm → endoscopic retrieval
	DJ Flexure	Twice weekly X-rays
If signs of Obstruction/Bleeding/ Perforation → urgent endoscopic retrieval +/- laparotomy		
Sharp Metallic Objects	Oesophagus	Urgent endoscopic retrieval
	Stomach and Duodenum	Urgent endoscopic retrieval
	DJ Flexure	Daily x-rays/ strict observation
		If fails to progress > 72 hrs → laparotomy
		If signs of Obstruction/Bleeding/ Perforation → laparotomy
Blunt Metallic Objects	Oesophagus	Endoscopic retrieval
	Stomach and Duodenum	If < 2cm → weekly X-rays/ conservative management
		If > 2 cm → observe with weekly X-rays for 1-2 months. If failure to progress → endoscopic retrieval
	DJ Flexure	Weekly X-rays/ conservative management
		If signs of Obstruction/Bleeding/ Perforation → urgent endoscopic retrieval +/- laparotomy

**CONCLUSION:**

Although the literature states that most foreign bodies in the general population usually pass spontaneously without the need for intervention, this study demonstrates a major difference within the prison population where surgical or endoscopic intervention was required in 36% of these patients (18% required a laparotomy, 9% required endoscopic intervention, and a further 9% required both endoscopic and open removal), in contrast to 1% in the general population<sup>1,2</sup>. Weiland *et al* conducted a 10 year study (Wisconsin, USA) on 22 male prisoners with a total of 256 ingested foreign bodies; 40% of the objects passed spontaneously, 30% were managed endoscopically whereas 30% required surgery<sup>7</sup>. Similarly Barros *et al* conducted a 6-year study (Madrid, Spain) where 167 patients (including 70 prisoners) were reviewed. Surgery was required in 30% of the patients<sup>3</sup>.

Identification of prisoners who have a pre-incarceration tendency to swallow foreign objects or those who repeatedly ingest objects, and subjecting them to psychiatric and behaviour modification therapy may prove efficacious. However, this was not assessed in this study.

The authors have no conflict of interest.

**REFERENCES**

- Pavlidis TE, Marakis GN, Triantafyllou A, Psarras K, Kontoulis TM, Sakantamis AK. Management of ingested foreign bodies: how justifiable is a waiting policy? *Internet J Surg* 2007;**9**(1).
- Eisen GM, Baron TH, Dominitz JA, Feigel DO, Goldstein JL, Johanson JF *et al*; American Society for Gastrointestinal Endoscopy. Guideline for the management of ingested foreign bodies. *Gastrointest Endosc* 2002;**55**(7):802-6.
- Barros JL, Caballero A Jr., Rueda JC, Monturiol JM. Foreign body ingestion: management of 167 cases. *World J Surgery* 1991;**15**(6):783-8.
- O'Donnell ME, Gibson N, Sharif MA, Spence RA, Lee J. Crohn's disease of the terminal ileum: a cheap diagnosis. *Ir J Med Sci Epub* 2007 Aug 18.
- Blaho KE, Merigian KS, Winbery SL, Park LJ, Cockrell M. Foreign body ingestion in the Emergency Department: case reports and review of treatment. *J Emerg Med* 1998;**16**(1): 21-6.
- Abraham B, Alao AO. An unusual foreign body ingestion in a schizophrenic patient: case report. *Int J Psychiatry Med* 2005;**35**(3):313-8.
- Weiland ST, Schurr MJ. Conservative management of ingested foreign bodies. *J Gastrointest Surg* 2002;**6**:496-500.
- Magdalena Castineira C, Magdalena Lopez C. [Foreign body ingestion among prisoners] Spanish. *Rev Esp Enferm Dig* 1994;**85**(4):254-6.
- Murshid KR, Khairy GE. Laparoscopic removal of a foreign body from the intestine. *J R Coll Surg Edinb* 1998;**43**(2):109-11.
- Sinnatamby CS, Editor *Last's Anatomy: Regional and Applied*. 10<sup>th</sup> ed. London: Churchill Livingstone: 2003. p. 241-56.
- Faigel DO, Stotland BR, Kochman ML, Hoops T, Judge T, Kroser J *et al*. Device choice and experience level in endoscopic foreign object retrieval: an in vivo study. *Gastrointest Endosc* 1997;**45**(6):490-2.
- Zuloaga J, Olivera J, Candia A, Arias V, De la Fuente A. [Ingestion of foreign bodies in a prison population; surgical treatment] Spanish. *Rev Esp Enferm Apar Dig* 1987;**72**:617-21.
- Litovitz TL. Battery ingestions: product accessibility and clinical course. *Pediatrics* 1985;**75**(3):469-76.
- Namasivayam S. Button battery ingestion: a solution to a management dilemma. *Pediatr Surg Int* 1999;**15**(5):383-4.