

Review

Magnet induced perforated appendicitis and ileo-caecal fistula formation.

Andrew J Robinson, Janne Bingham, Ronald LE Thompson

Accepted 1 September 2008

ABSTRACT

Foreign body ingestion is a common paediatric problem. In the majority of cases spontaneous passage occurs. Magnet ingestion is rare and solitary magnet ingestion usually does not cause any complications. A number of gastrointestinal complications have been reported, such as fistula formation, perforation and volvulus following multiple magnet ingestion. We review magnet ingestion and describe the first case in the literature of magnet induced perforated appendicitis with an associated ileo-caecal fistula.

Keywords: appendicitis, foreign body ingestion, magnets, small bowel fistula.

INTRODUCTION

Foreign body ingestion is frequent in children, particularly in those aged between 6 months and 3 years and is generally associated with little or no morbidity^{1,2}. Fortunately, in 80% of cases, spontaneous passage will occur. However, 10% to 20% require endoscopic retrieval and in 1% of cases there may be complications requiring surgical intervention, such as intestinal obstruction, perforation or fistula formation³.

Appendicitis is the commonest surgical emergency. The diagnosis is predominantly a clinical one. However, not all patients present in a typical manner. The cause of appendicitis is unknown but is thought to be multifactorial: luminal obstruction, dietary and familial factors have all been suggested⁴.

ILLUSTRATIVE CASE REPORT:

A three year old boy was admitted to the paediatric surgical ward at a District General Hospital giving a one day history of acute crampy abdominal pain which was worse in his right side. The pain was associated with anorexia and four episodes of non-bilious vomiting. His last bowel motion was three days prior to admission (not unusual for this child). He was noted to be generally lethargic and reported a five day history of a non-productive cough and a one day history of a wheezy chest. This was associated with intermittent temperatures and coryzal symptoms. He had no past medical history.

On examination he was pyrexia with a temperature of 38.8°C. His abdomen was soft and non-tender. There was no peritonism, abdominal distension or organomegaly. Bowel sounds were present and normal.

Initial investigations showed a leucocytosis of $14.64 \times 10^9/L$

(reference range 4.0 – 11.0) and an elevated C - reactive protein of 92 mg/L (reference range 0 – 10). His electrolyte profile was normal. Urinalysis showed ketones and a trace of blood.

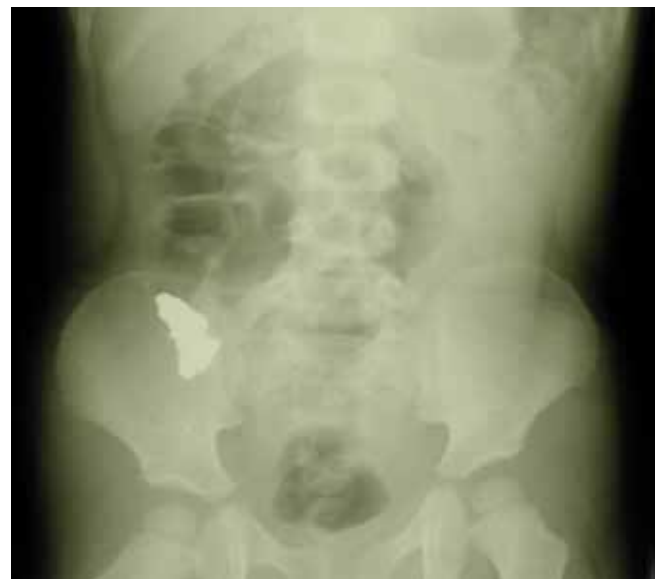

Fig 1. Abdominal X-ray: demonstrating a foreign body in the region of the ileo-caecal valve. There was no small bowel dilatation and there was air in the rectum.

Radiological investigations performed were an erect chest X-ray and plain abdominal X-ray. His chest X-ray showed no pneumoperitoneum and his abdominal film showed what appeared to be a foreign body in the region of the ileo-caecal valve (figure 1). It did not show any small bowel dilatation and there was gas evident in the rectum.

Initially, the boy was admitted for observation and conservative management. The following morning he was in severe pain, with right iliac fossa tenderness and localised peritonitis. He proceeded to laparotomy through a Lanz incision in the right iliac fossa. There was peritoneal contamination with turbid fluid, a perforation at the proximal end of the appendix was noted and there was an ileo-caecal

Department of Surgery, Altnagelvin Area Hospital, Glenshane Road, Londonderry, United Kingdom.

Correspondence to: Mr Robinson

arobinson13@hotmail.co.uk

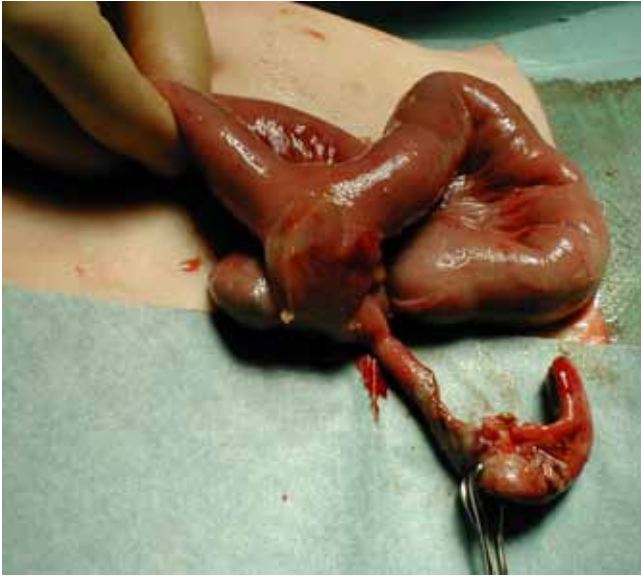


Fig 2. Intra-operative photograph demonstrating an ileo-caecal fistula and perforated appendix

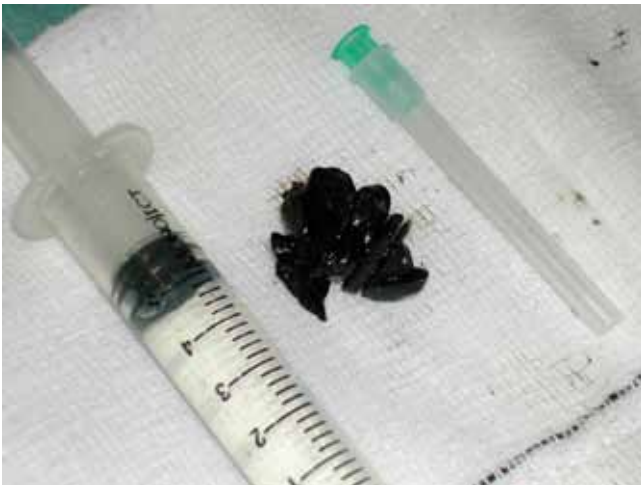

Fig 3. Foreign bodies found in the caecum and ileum, which turned out to be magnets

fistula found 5cm proximal to the ileo-caecal valve (figure 2). Foreign bodies, which after removal were found to be magnets, were found in the caecum and in the terminal ileum (figure 3).

The appendix was resected and the fistula was taken down. Defects in the caecum and ileum were oversewn and peritoneal lavage was performed prior to closure of the abdomen. Post operative recovery was uneventful and the asymptomatic ileo-caecal fistula was coincidental.

On questioning the child's mother after the operation, it transpired that his elder sister had brought magnets home from a school trip some 3-4 months previously. We hypothesised that the boy had swallowed several magnets 3 - 4 months prior to his hospital admission.

DISCUSSION:

Ingestion of foreign objects is more common in children than in adults. There are about 100,000 cases annually in the United States of foreign body ingestion, with over 80% of these

occurring in the paediatric population³. Historically, treatment algorithms for ingested foreign bodies have documented that the vast majority, approximately 80% of foreign bodies reaching the stomach, pass through the gastrointestinal tract spontaneously⁵. These patients can therefore usually be observed for the development of symptoms. Objects swallowed vary considerably and those that cause perforation can range from accidental cocktail stick ingestion⁶, food such as chicken bones⁷ right through to dangerous objects including razorblades and more serious items⁸.

Magnet ingestion is rare. There have been thirteen reported cases. A history of solitary magnet ingestion usually does not cause any complications, but multiple magnet ingestion causes problems. Even though the majority of magnets are small enough to pass through the gastrointestinal tract, complications arise when magnets get separated as they pass through the pylorus into duodenum.

The pathogenesis of the complications is the attraction of two or more magnets across the walls of multiple loops of bowel. This causes ischaemia and necrosis of the pinched bowel wall leading to ulceration and eventually perforation or fistulation. Magnet ingestion has resulted in obstruction, fistula formation, ulceration, perforation, volvulus of the small and large intestine and strangulation of adjacent loops of small bowel between the attracted segments^{1-3, 9-12}.

Clinically, it is safe to observe the ingestion of a solitary magnet that has reached the stomach. The ingestion of multiple magnets should prompt immediate referral for endoscopy and attempted removal^{1,11}. Magnets in the stomach can generally be removed via endoscopy and a magnetic tube. For those that have passed into the duodenum and travelled more distally, careful observation with serial abdominal X-rays is accepted initial management. Once symptoms of increasing abdominal pain or signs of intestinal obstruction or perforation develop then prompt exploratory laparotomy should be performed⁹.

There are no reports of magnet ingestion being associated with or causing appendicitis. We believe the mechanism in this case was luminal obstruction by a magnet occluding the appendix orifice, leading to its perforation.

CONCLUSION.

Magnet ingestion is rare. Multiple magnets within the stomach require endoscopic retrieval in an attempt to avoid subsequent complications. Once multiple magnets have entered the small bowel, they can cause numerous gastrointestinal complications including perforation of the appendix and fistula formation.

The authors have no conflict of interest.

REFERENCES:

1. Wildhaber BE, Le Coultré C, Genin B. Ingestion of magnets: innocent in solitude, harmful in groups. *J Pediatr Surg* 2005;**40**(10):e33-35.
2. Hernández Anselmi E, Gutiérrez San Román C, Barrios Fontoba JE, Ayuso González L, Valdés Dieguez E, Lluna González J, Roca Molla A, García-Sala Viguer C, Gómez Montes J, Cortina Orts H. Intestinal perforation caused by magnetic toys. *J Pediatr Surg* 2007;**42**(3):E13-6.
3. Butterworth J, Feltis B. Toy magnet ingestion in children: revisiting the algorithm. *J Pediatr Surg* 2007;**42**(12):E3 - E5.

4. Larner AJ. The aetiology of appendicitis. *Br J Hosp Med* 1988;**39(6)**:540-542.
5. Vijaysadam V, Perez M, Kuo D. Revisiting Swallowed Troubles: Intestinal complications caused by two magnets – A case report, review and proposed revision to the algorithm for the management of foreign body ingestion. *J Am Board Fam Med* 2006;**19(5)**:511-516.
6. Lindsay R, White J, Mackle E. cocktail stick injuries – the danger of half a stick. *Ulster Med J* 2005;**74(2)**:129-131.
7. Aktar S, McElvenna N, Gardiner KR, Irwin ST. Bowel perforation caused by swallowed chicken bones – a case series. *Ulster Med J* 2006;**76(1)**:37-38.
8. Bisharat M, O'Donnell ME, Gibson N *et al*. Foreign body ingestion in prisoners – the Belfast experience. *Ulster Med J* 2008;**77(2)**:110-4.
9. Chung JH, Kim JS, Song YT. Small bowel complication caused by magnetic foreign body ingestion of children: two case reports. *J Pediatr Surg* 2003;**38(10)**:1548 – 1550.
10. Lee SK, Beck NS, Kim HH. Mischievous magnets: unexpected health hazard in children. *J Pediatr Surg* 1996;**31(12)**:1694-95.
11. Pryor HI, Lange PA, Bader A, Gilbert J, Newman K. Multiple magnetic foreign body ingestion: a surgical problem. *J Am Coll Surg* 2007;**205(1)**:182-6.
12. Nui A, Hiramata T, Katsuramaki T, Maeda T, Meguro M, Nagayama M, Matsuno T, Mizumoto T, Hirata K. An intestinal volvulus caused by multiple magnet ingestion: an unexpected risk in children. *J Pediatr Surg* 2005;**40(9)**:e9-11.