

Case Report

Mesenteric vein thrombosis associated with anti-thrombin III deficiency

Kelly-Ann Eastwood, Alison Vaughan, Kenneth H McCune

Accepted 27 August 2008

INTRODUCTION

Acute mesenteric ischaemia presents infrequently in clinical practice accounting for 1-2 cases per 1000 hospital admissions per year¹. Of these, mesenteric vein thrombosis (MVT) is responsible for between 5% and 15% of intestinal ischaemic events².

Primary mesenteric vein thromboses are typically seen in patients with thrombophilias due to protein C, protein S and anti-thrombin III deficiency. Approximately 2% of primary MVT cases are caused by anti-thrombin III deficiency³. Secondary MVT is commonly seen post-operatively, with oral contraceptive use, trauma or in paraneoplastic syndromes.

Despite advances in diagnostic techniques and management of this disease, the prognosis remains poor with mortality rates ranging from 20% to 93%^{2,4}. We describe a case of primary MVT attributable to anti-thrombin III deficiency.

CASE REPORT

A 49-year-old man was admitted with a two-day history of worsening abdominal pain associated with nausea, vomiting, and constipation. His past medical history revealed a background of two proximal deep venous thromboses (DVT) and an earlier diagnosis of anti-thrombin III deficiency. He smoked over 30 cigarettes per day and consumed more than 30 units of alcohol per week. He had a family history of anti-thrombin III deficiency and many family members were already taking life long anticoagulation (figure 1). The patient had been previously warfarinised following his DVTs, but latterly had been non-compliant. On examination he was normotensive but tachycardic with abdominal distension, guarding and absent bowel sounds. The degree of subjective pain was disproportionate to his objective tenderness. Digital rectal examination was unremarkable. Initial investigations revealed a leucocytosis and elevated C-reactive protein. A plain abdominal radiograph showed dilated bowel loops in the left flank. Treatment with intravenous fluids, analgesia, anti-emetics and broad-spectrum antibiotics was commenced. An emergency computed tomograph of his abdomen was carried out in the portal venous phase; this showed thrombosis in the superior mesenteric vein extending to the portal confluence (figure 2) but the portal vein was patent. Small bowel loops

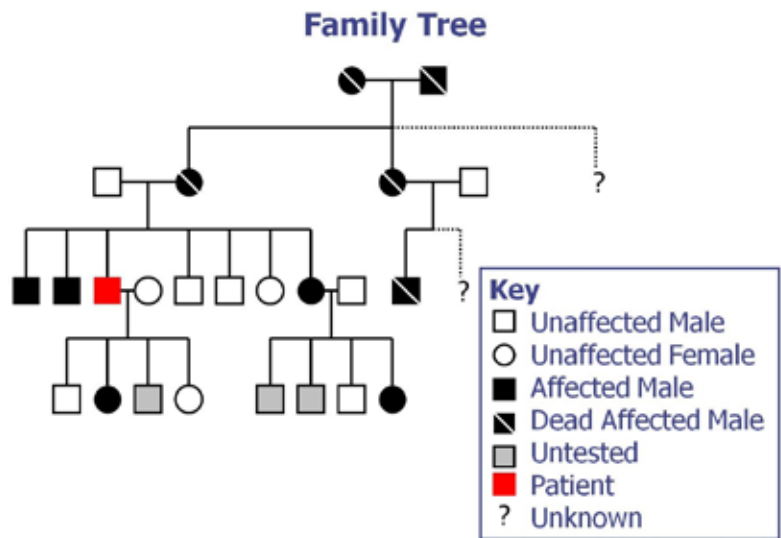


Fig 1. Anti-thrombin III deficiency in this patient's family

were dilated and oedematous, although not clearly necrotic, and there was free fluid in abdomen and pelvis. On the basis of the clinical presentation and radiological findings, the patient was taken to theatre for a laparotomy. Intra-operatively a clearly demarcated venous infarct of the mid small bowel was found. A small bowel resection with primary anastomosis was performed. The pathology report of the resected specimen confirmed small intestinal haemorrhage and infarction with marked transmural inflammatory cell infiltrate.

Post-operatively he was transferred to the intensive care unit where he subsequently developed a severe systemic inflammatory response. Over a period of several days, his clinical and biochemical parameters suggested ongoing sepsis but the aetiology of this was unclear. He therefore underwent a second look laparotomy, but no evidence of further bowel infarction was found. Throughout his admission to the intensive care unit, the patient received full systemic support and was anti-coagulated with low molecular weight heparin.

Department of General and Vascular Surgery, Altnagelvin Area Hospital, Londonderry, United Kingdom.

Correspondence to Kenneth McCune

khmccune@msn.com

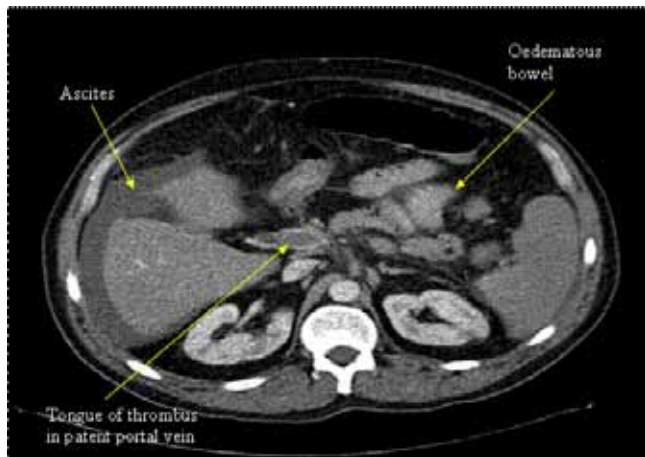


Fig 2. Abdominal CT showing tongue of thrombus extending into portal vein, bowel wall oedema and ascites.

The efficacy of anti-coagulation was monitored with factor Xa assays. Despite this, he developed multiple organ dysfunction syndrome and required increasing ventilatory support, dialysis and addition of inotropes. He also developed liver failure (although computed tomography showed no evidence of further extension of thrombus into the portal vein) and he eventually died four weeks after initial presentation.

DISCUSSION

Diagnosis of intestinal ischaemia requires a high index of suspicion, regardless of the underlying cause. Many cases of MVT do not require surgical intervention and the decision to operate is based largely on clinical grounds where there is a strong possibility of bowel infarction. Attempts can be made to refine the diagnosis by blood testing; patients may present with a raised white cell count or metabolic acidosis, but neither is sensitive nor specific enough to aid definitive diagnosis of MVT. Elevated D-dimer concentrations may also indicate bowel ischaemia, but similarly are not specific for MVT⁵. Imaging modalities such as plain abdominal radiography can demonstrate bowel wall oedema and may exclude other causes of abdominal pain. CT angiography is a more sensitive test for diagnosing thrombosis than CT or angiography alone. Magnetic resonance angiography is under review as a possible diagnostic tool for mesenteric ischaemia, but it lacks the resolution needed to diagnose non-occlusive mesenteric ischaemia or distal embolic disease.

The mainstay of medical management is anticoagulation, and immediate heparinisation has been shown to reduce recurrence and progression of the disease⁶. However, use of heparin is more complicated in the context of anti-thrombin III deficiency, as patients with reduced concentrations of anti-thrombin III are likely to be resistant to the effects of heparin and require larger doses. This may be attributable to the action of heparin, which binds to anti-thrombin, causing it to activate and inhibit thrombin. Anti-thrombin concentrate has been used effectively in patients with this deficiency and acute venous thrombosis, yet its use as an adjunctive therapy or alternative to heparin has not been studied in a controlled trial.

Thrombolysis with streptokinase, urokinase and tissue plasminogen activator (t-PA) has been used in treatment of

MVT, though authors have recommended that its use be restricted to symptomatic patients with early diagnoses. Various routes for infusion of thrombolytics are described, including indirect intra-arterial infusion through the superior mesenteric artery and direct access to the portal vein with percutaneous transhepatic and transjugular-intrahepatic approaches. It is felt that trans-arterial infusions are generally safer as they avoid potential bleeding complications that can result from liver puncture during the procedure, however indirect lysis may be more unpredictable because of flow into collaterals⁷. These methods are preferred to use of systemic thrombolysis, owing to reduced haemorrhagic risk.

A further treatment option is mechanical thrombectomy, which provides a non-pharmacological alternative for treatment of MVT, particularly in patients who pose high risks for thrombolytic therapy. A combined approach using catheter-directed thrombolysis and mechanical thrombectomy has also been attempted with success though large-scale trials have not been undertaken⁸.

Patients presenting with peritonitis or identifiable bowel infarction on CT require surgical management^{2,9,10}. Options for surgical management of MVT include bowel resection with primary anastomosis, temporary stoma formation, thrombectomy, or a combination of these techniques. The choice of surgical management depends on the extent of bowel infarction, bowel viability and whether it is possible following bowel resection to form a stoma^{2,10}. It is also often difficult to absolutely ascertain bowel viability, although it can be assessed by direct observation of colour, presence of capillary refill and bowel contractility. This can be unreliable and can lead to more bowel resection than necessary^{9,10}. There remains no consensus on whether or not a primary anastomosis should be attempted or a stoma created at the time of laparotomy¹⁰.

Open thrombectomy is rarely undertaken as not all of the thrombus can be removed^{2,9,10}, but its use in the treatment of acute superior mesenteric vein thrombosis when the thrombus is recently formed and restricted to the SMV may reduce the need for extensive bowel resection. Laparoscopy has been suggested as a diagnostic tool in identifying bowel ischaemia, but as it necessitates raising the intra-abdominal pressure and therefore decreasing mesenteric blood flow, it is probably best-avoided².

Diagnosis and management of primary MVT is complex. The condition may progress to full-blown portal vein thrombosis with more complications and a higher mortality. This case highlights the need to identify patients with MVT accurately and efficiently with clear implementation of medical and surgical management, and how, even with apparently optimal treatment, the outcome may still be fatal.

The authors have no conflict of interest to declare

REFERENCES

1. Stoney RJ, Cunningham CG. Acute mesenteric ischemia. *Surgery* 1993;**114**(3):489-490.
2. Kumar S, Sarr MG, Kamath PS. Current concepts: mesenteric venous thrombosis. *N Engl J Med* 2001;**345**(23):1683-8.
3. Morasch M, Ebaugh JL, Chiou AC *et al*. Mesenteric venous thrombosis: A changing clinical entity. *J Vasc Surg* 2001;**34**(4):680-684.

4. Brandt LJ, Boley SJ. AGA technical review on intestinal ischemia. American gastrointestinal association *Gastroenterology* 2000;**118**(5):954-968.
5. Acosta S, Nilsson TK, Björck M. Preliminary study of D-dimer as a possible marker of acute bowel ischaemia. *Br J Surg* 2001;**88**(3):385-388.
6. Hrstic I, Kalauz M, Cukovic-Cavka S, Ostojic R, Banfic L, Vucelic B. Treatment of extensive subacute portal, mesenteric and ileocolic vein thrombosis with recombinant tissue plasminogen activator. *Blood Coagul Fibrinolysis* 2007;**18**(6):581-583.
7. Sze D, O'Sullivan GJ, Johnson DL, Dake MD. Mesenteric and portal venous thrombosis treated by transjugular mechanical thrombolysis. *Am J Roentgenol* 2000;**175**(3):732-734.
8. Lopera JE, Correa G, Brazzini A, Ustunsoz B, Patel S, Janchai A, Castaneda-Zuniga W. Percutaneous transhepatic treatment of symptomatic mesenteric venous thrombosis. *J Vasc Surg* 2002;**36**(5):1058-1061.
9. Clavien PA. Diagnosis and management of mesenteric infarction *Br J Surg* 1990;**77**(6):601-603.
10. Menon NJ, Amin AM, Mohammed A, Hamilton G. Acute mesenteric ischaemia. *Acta Chir Belg* 2005;**105**(4):344-354.