

Case Report

# Kikuchi-Fujimoto Disease (Cervical Subacute Necrotising Lymphadenitis): An important benign disease often masquerading as lymphoma

William J Primrose<sup>1</sup>, Seamus S Napier<sup>2</sup>, Alyson J Primrose<sup>1</sup>

Accepted 20 January 2009

---

## ABSTRACT

**Objectives:** We describe a rare cause of posterior triangle cervical lymphadenopathy in a third decade female, outline the clinical and histopathological features and discuss excision biopsy as the investigation of choice in this age group, with lymphoma as the diagnosis of exclusion.

**Case report:** A thirty-four year old female was referred to our Head and Neck clinic with a one-month history of left posterior triangle lymphadenopathy. She reported no other symptoms and haematological investigations were normal. She was “Red Flagged” as a possible lymphoma. Excision biopsy revealed extensive histiocytic necrotising lymphadenitis providing a diagnosis of Kikuchi-Fujimoto disease.

**Conclusions:** Persistent posterior triangle lymphadenopathy in the 16-40 year old age group warrants “Red Flag” referral to rule out serious pathology such as HIV, metastatic cancer or lymphoma. When the ENT examination and haematological work up is negative, we advocate proceeding straight to excision biopsy as the quickest way to obtain a diagnosis, which sometimes comes up with the unexpected as in this rare case of Kikuchi-Fujimoto disease.

**Key Words:** Kikuchi-Fujimoto disease, cervical lymphadenopathy, Red Flag referral, Excision biopsy.

---

## INTRODUCTION

Persistent cervical lymphadenopathy is an important “Red Flag” referral criterion to Head and Neck Clinics. In adults over the age of 40, when lesions of thyroid and salivary glands are excluded, the majority (75%) of neck lumps are malignant. Metastatic lymphadenopathy from a carcinoma of the aerodigestive tract is of particular significance in this age group, especially if there is a history of heavy smoking and drinking, and localisation of the primary tumour must be made without delay. In contrast, cervical lymphadenopathy in patients aged between 16-40 years is most commonly the result of infection; other causes in this age group include rare inflammatory processes and neoplastic lesions such as lymphoma.

We describe a 34-year-old woman who presented with cervical lymphadenopathy due to Kikuchi-Fujimoto disease (KFD, or subacute necrotising histiocytic lymphadenitis), a rare and important cause of benign lymph node enlargement.

## CASE REPORT

A 34-year-old female became aware of lump in her left lower neck in mid May 2008. She attended her General Practitioner approximately 4 weeks later who noted the presence of two enlarged lymph nodes low on the left side of her neck, which were painless, firm but mobile; he also felt a lump in her right axilla. She was afebrile, haematological investigations at that time revealed a haemoglobin of 12.9g/dl, white cell count of

$4.1 \times 10^9/l$  with normal differential and an ESR of 12 mm/hr. The patient was a non-smoker who denied any weight loss, itching or night sweats and was in otherwise good health. She was referred as a “Red Flag” case of possible lymphoma to the local Head & Neck clinic, where she was seen 5 days later. Clinical examination at that time confirmed a 2 cm diameter prominent painless rubbery lymph node in the left posterior triangle and several similar but smaller lymph nodes just above and below this largest lymph node. There was a mild operculitis of her partially erupted lower wisdom teeth but nil else of note within her mouth or throat. In particular, there was no lesion on her scalp or neck skin and no axillary or groin lymphadenopathy was detected. She had no other complaints and still felt well. The clinical suspicion of lymphoma persisted in spite of the absence of other symptoms or signs and an excision biopsy was performed three days later.

At surgery, an enlarged friable 2cm lymph node was found in Level V, removed and submitted for histopathological assessment. The most striking feature of the lymph node on microscopy was the presence of extensive areas of geographic necrosis bounded by relatively broad zones of histiocytes

---

<sup>1</sup>Eye and Ear Clinic, and <sup>2</sup>Department of Pathology, Royal Victoria Hospital, Belfast BT12 6BA.

Correspondence to Mr Primrose

bprimrose@btinternet.com

and activated lymphoid cells. Many apoptotic cell fragments were present being ingested by histiocytes (Figure 1) but there was no neutrophil infiltrate, multinucleate giant cell formation or granulomatous inflammation. In other areas of the node, there was expansion of the paracortical regions with many dispersed histiocytic cells; only a few small reactive lymphoid follicles were present. The histopathology suggested a necrotising lymphadenitis without neutrophil infiltration, virtually diagnostic of KFD - occasionally such changes can be associated with systemic conditions, in particular systemic lupus erythematosus (SLE). The patient was tested for autoantibodies including ANA, the most commonly detected autoantibody in SLE; the results were negative. The patient was followed-up for six months and made a spontaneous uneventful recovery.

## DISCUSSION

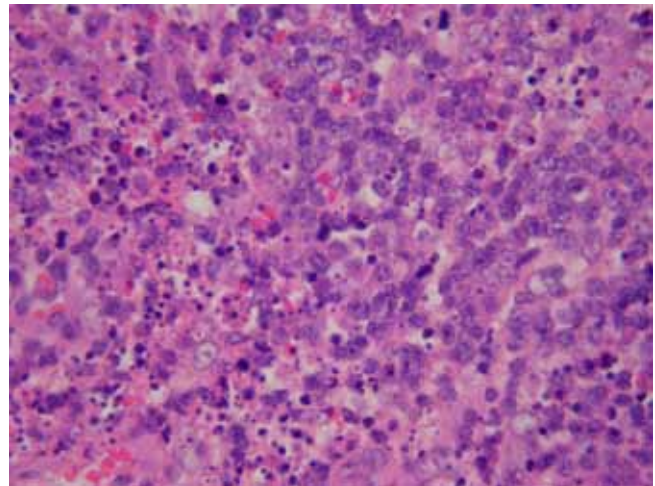
The differential diagnosis of enlarged cervical lymph nodes is wide and a full discussion is beyond the scope of this article but the principal conditions to be distinguished in posterior triangle lymphadenopathy are lymphoma, metastatic tumour from the scalp or more distant site, drainage phenomena from infective lesions in the dependent skin, and systemic reactive conditions such as infectious mononucleosis, human immunodeficiency virus (HIV) infection and rubella.

In this case there was no history of previous surgery or clinical findings suggesting metastasis from tumour elsewhere; there were no oral or head and neck manifestations to suggest systemic viral infection, including HIV. There was no skin lesion in the drainage area to indicate a local inflammatory cause for the lymph node enlargement and the intraoral inflammation related to the partially erupted third molars was not thought to be contributory. Given the absence of systemic upset, no serological investigation of specific viral infection markers was preformed.

KFD was first described independently in 1972 by Kikuchi<sup>1</sup> and Fugimoto<sup>2</sup>. In 1982 the first cases of KFD were reported in North America and Europe<sup>3</sup> and the disease is now recognised worldwide. KFD commonly affects young women with a peak age of incidence occurring in the third decade<sup>4</sup>, but rarely affects patients under 16 years of age. A handful of cases have been reported in children under the age of ten. The ratio of disease occurrence between females and males is 4:1, although less apparent gender differences occur in Asian populations when compared to Western populations.

The aetiology of KFD remains unclear. Several infective agents including EBV, parvovirus B19 and HHV-6<sup>5</sup>, have been postulated as causative although no relationship has yet been established. Due to the similar histology seen in KFD and the lymphadenitis of SLE and that both diseases most often occur in young females, Dorfman and Berry<sup>6</sup> suggested KFD could be an attenuated form of SLE. Another explanation<sup>7</sup> proposed that KFD might be a self-limiting SLE-like autoimmune reaction to viral infected transformed lymphocytes. Whatever the pathogenesis, it is likely that the development of KFD is a multifactorial process involving environmental, biological and genetic influences.

The majority of patients with KFD present with cervical lymphadenopathy usually of 1 - 4 cm in diameter, the



*Fig 1. High power view of area of necrosis showing many histiocytes packed with cell fragments but without neutrophil infiltration. (H&E, x 400 original magnification)*

posterior cervical triangle being the most commonly affected site<sup>8</sup>. Other less common signs and symptoms include splenomegaly, fever and weight loss – one third of patients have a rash at presentation, findings that can heighten the clinical overlap with infectious mononucleosis, SLE and lymphoma. A number of non-specific haematological abnormalities may occur in KFD. Approximately 50% of cases show a mild neutropenia<sup>9</sup> with leucopaenia also present in 25-40% of cases<sup>4</sup>. Other non-specific findings include a raised CRP and ESR but their absence does not exclude KFD.

Fine needle aspiration cytology (FNA) has been able to provide a diagnosis in cases of KFD but correct interpretation depends on sampling affected areas of the node and in many cases the exclusion of non-Hodgkin's lymphoma may not be possible on FNA alone. In our opinion there should be a low threshold for open excision biopsy in patients less than forty years of age presenting with persistent lymphadenopathy. In this age group FNA can often be an additional non-diagnostic step, delaying the excision biopsy, which is required for the accurate diagnosis. In our case, we proceeded directly to open biopsy for this reason.

The histopathological features of KFD are quite distinctive and the only mimic is SLE lymphadenitis. The lymph node changes in Kawasaki disease (mucocutaneous lymph node disease), cat scratch disease and atypical mycobacterial infection are quite different, being characterised by intravascular fibrin thrombi and neutrophils, stellate microabscesses with neutrophils and necrotising stellate granulomatous inflammation respectively<sup>10</sup>.

## CONCLUSION

We describe a case of KFD presenting as an unusual cause of posterior triangle cervical lymphadenopathy that mimicked lymphoma. Whilst the histopathological findings were classical and allow the diagnosis of KFD to be achieved without difficulty, the case highlighted the usefulness of prompt referral for biopsy of persistent unexplained lymphadenopathy.

The authors have no conflict of interest.

## REFERENCES:

1. Kikuchi M. Lymphadenitis showing focal reticulum cell hyperplasia with nuclear debris and phagocytes: a clinico-pathological study. [Japanese] *Nippon Ketsueki Gakkai Zasshi* 1972;**35**:379-80.
2. Fujimoto Y, Kojima Y, Yamaguchi K. Cervical subacute necrotizing lymphadenitis. A new clinicopathological entity. *Naika* 1972;**20**:920-7.
3. Pileri S, Kikuchi M, Helbron D, Lennert K. Histiocytic necrotizing lymphadenitis without granulocytic infiltration. *Virchows Arch A Pathol Anat Histol* 1982;**395**(3):257-71.
4. Scheinfeld NS. Cutaneous Kikuchi disease. Updated Feb 12 2008. *emedicine Medscape* Available from: <http://emedicine.medscape.com/article/1124957-overview>. Last accessed Feb 2009.
5. Qadri F, Atkin GK, Thomas D, Das S.K. Kikuchi's disease: an important cause of cervical lymphadenopathy. *Clin Med* 2007;**7**(1):82-4.
6. Dorfman RF, Berry GJ. Kikuchi's histiocytic necrotizing lymphadenitis: an analysis of 108 cases with emphasis on differential diagnosis. *Semin Diagn Pathol* 1988;**5**(4):329-45
7. Imamura M, Ueno H, Matsuura A, Kamiya H, Suzuki T, Kikuchi K. et al. An ultrastructural study of subacute necrotizing lymphadenitis. *Am J Pathol* 1982;**107**(3):292-9.
8. Louis N, Hanley M, Davidson NM, Kikuchi-Fujimoto disease: a report of two cases and an overview. *J Laryngol Otol* 1994;**108**(11):1001-4.
9. Garcia CE, Girdhar-Gopal HV, Dorfman DM. Kikuchi-Fujimoto disease of the neck. Update. *Ann Otol Rhinol Laryngol* 1993;**102**(1):11-5
10. Chang KL, Arber DA, Gaal KK, Weiss LM. Lymph nodes and spleen. In: Silverberg SG, DeLellis RA, Frable WJ, LiVolsi VA, Wick MR, editors. *Silverberg's Principles and practice of surgical pathology and cytopathology*. Volume 1. New York: Churchill Livingstone; 2006: 507-607.