

Paper

# Laparoscopic Cardiomyotomy for Achalasia: A Single Unit study

R Kennedy, C Menezes, J Ahmad, JA Kennedy

Accepted 15 September 2009

## ABSTRACT

**Aims** Achalasia is a rare incurable neuromuscular disorder of the oesophagus. A number of treatment options are available. We reviewed our results of laparoscopic cardiomyotomy over a 30 month period.

**Methods** 18 patients with manometric features of achalasia underwent surgery between 2004 and 2006. Pre and postoperative weight and dysphagia scores were recorded (maximum score 45=normal, 0=complete dysphagia). Change in the Body Mass Index (BMI) was measured. Other symptoms (heartburn, epigastric pain, regurgitation, odynophagia and sleep disturbance) were scored on a 0-4 scale of increasing severity.

**Results** At mean follow up of 16.2 months the mean dysphagia score was significantly improved from 7.5 to 33.9 ( $p<0.005$ ). BMI was significantly increased from 22.3 to 25.8 kg/m<sup>2</sup> ( $p<0.05$ ). Scores for heartburn, epigastric pain, regurgitation, odynophagia and sleep disturbance were also significantly improved. The average inpatient stay was 3.1 days and average operating time 111 minutes. One mucosal perforation occurred which was repaired intraoperatively. No patients required secondary operative intervention.

**Conclusions** Laparoscopic cardiomyotomy is a safe, highly effective, minimally invasive treatment for achalasia.

## INTRODUCTION

Achalasia is an incurable neuromuscular disorder of the oesophagus resulting from destruction of the oesophageal myenteric plexus.<sup>1</sup> This results in aperistalsis and failure of the lower oesophageal sphincter to relax following swallowing. Symptoms are gradual in onset and include dysphagia, odynophagia, regurgitation, sleep disturbance and weight loss. The annual incidence is about 1 in 100,000 people with an equal sex incidence. It tends to present in adult life between about 25 and 40 years old with less than 5% occurring in children.<sup>2,3</sup>

Manometry provides the definitive diagnosis. The classic features are an adynamic oesophagus, hypertensive lower oesophageal sphincter (LOS) and failure of the LOS to relax on swallowing. An oesophagogastroduodenoscopy (OGD) should also be performed to investigate for malignant disease.<sup>4</sup> Untreated, it leads to an extremely poor quality of life because of progressive dysphagia, oesophageal dilatation, stasis and aspiration. All current treatments are palliative and aim to reduce the pressure at the LOS.<sup>5</sup>

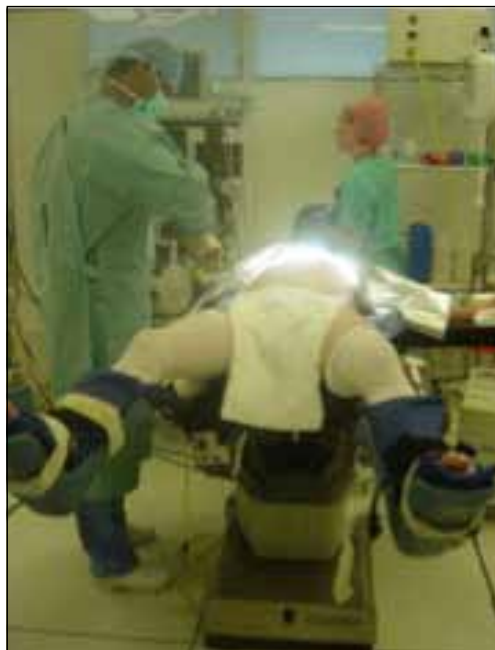

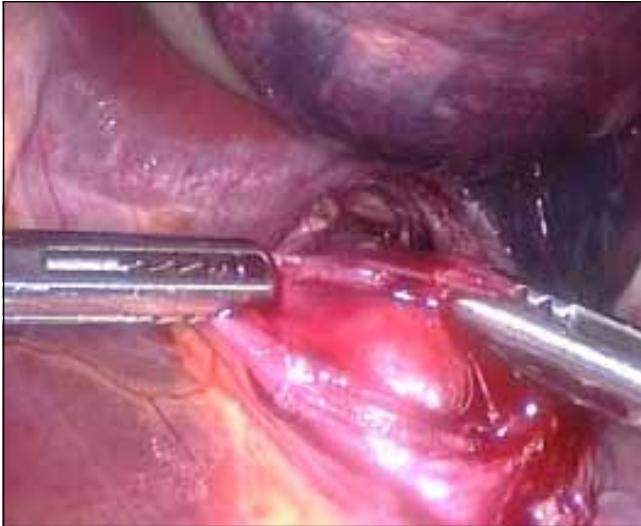
Fig 1. Patient position The patient is positioned supine with legs spread apart.

Medical therapies include the use of calcium antagonists or sildenafil to relax the smooth muscle of the LOS, however results are poor.<sup>6</sup> Endoscopic procedures include pneumatic dilatation and injection of Botulinum Toxin. These produce acceptable short term results but long term success is limited and the majority of patients will require several interventions.<sup>7</sup> Surgical treatment aims to divide the muscle of the LOS longitudinally. This can be achieved via the transabdominal, transthoracic or thoracoscopic routes. It has been suggested that the laparoscopic transabdominal route is associated with a low rate of failure and complication and a high chance of success.<sup>8</sup> We review here our results and experience with laparoscopic cardiomyotomy for achalasia.

Department of Upper Gastrointestinal Surgery, Royal Victoria Hospital, Grosvenor Road, Belfast BT12 6BA

rpg.kennedy@btinternet.com

Correspondence to Dr Kennedy



*Fig 2.* Extension of the myotomy. The split edges of oesophageal sphincter muscle are shown grasped by forceps. The oesophageal mucosa lies between. A plane of cleavage is developed between these two layers.

### LAPAROSCOPIC CARDIOMYOTOMY: TECHNIQUE

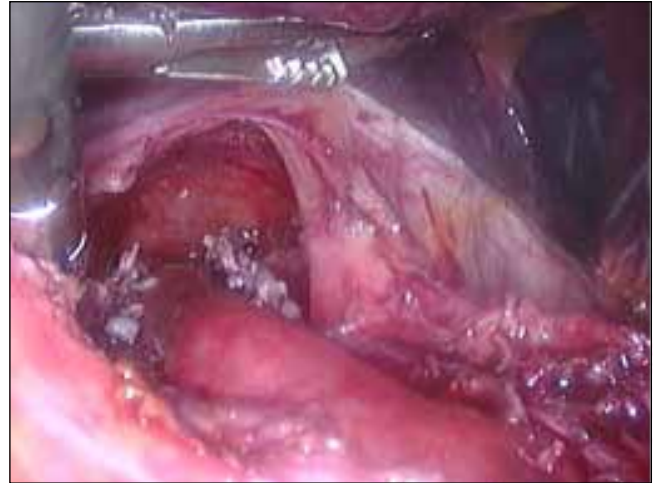
The procedure begins with the patient in a supine position. [figure 1] The surgeon stands between the patients' legs and the assistant to the patient's left. Pneumoperitoneum is achieved by optical 10mm port insertion just below the left costal margin in the midclavicular line. An adjustable self-supporting liver retractor is inserted together with two 5mm ports and another 10mm port. The first step of the procedure is to display the oesophago-gastric junction to confirm the relevant anatomy. Then the phreno oesophageal ligament is divided with a harmonic scalpel, and the anterior oesophagus exposed. [figure 2] There is no need to mobilise

TABLE 1.

#### *The Royal Adelaide Dysphagia score.*

*Each food is given an increasing score based on its difficulty to swallow. The maximum score therefore indicates that the patient never has difficulty with any of the foods and therefore scores 45.*

Swallowing difficulty in:-	Always (x0)	Occasionally (x0.5)	Never (x1)
1-water			
2-milk/soup			
3-Custard/yoghurt			
4-Jelly			
5-scrambled egg/mash			
6-fish/boiled potatoes			
7-bread			
8-apple			
9-steak			

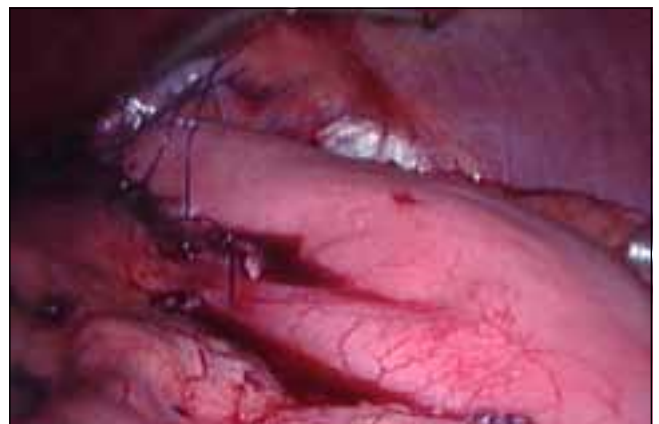


*Fig 3.* The completed myotomy. This extends into the mediastinum

the oesophagus circumferentially. The myotomy is then commenced and extended approximately 6cm proximal and 2 cm distal to the junction. The extent of the myotomy [figure3] is confirmed with intraoperative gastroscopy. A 180 degree anterior fundoplication (Dor patch) is then performed to prevent pathological reflux. [figure 4]. Port sites are infiltrated with local anaesthetic for post operative pain control in addition to oral analgesia. Oral fluids are commenced at 4 hours and soft diet at 24 hours.

### METHODS

18 patients with manometric features of achalasia underwent surgery between 2004 and 2006. Pre and postoperative weight and dysphagia scores were recorded. Patients were contacted post-operatively by telephone by one of the authors working in the unit (RK) and a structured questionnaire carried out. The Royal Adelaide Dysphagia Score<sup>9</sup> was chosen as the investigative instrument. It provides an explicit functional measure of swallowing. The maximum score is 45 indicating normal swallowing. The minimum score is 0 indicating complete dysphagia. [table 1] Change in the Body Mass Index (BMI) was measured along with other common symptoms (heartburn, epigastric pain, regurgitation, odynophagia and sleep disturbance) which were scored on a 5 point 0-4 Likert scale of increasing severity.



*Fig 4.* Anterior fundoplication (Dor patch).The fundus of the stomach is secured to the right crus of the diaphragm with non absorbable stitches.

## STATISTICAL ANALYSIS

The means of all continuous variables were compared by appropriate parametric or non parametric tests. Categorical variables and proportions were compared the Chi Squared test or the Fischer exact test. Results are expressed as medians and as means +/- SD. Differences were considered significant at  $p < 0.05$

## RESULTS

The mean age of the patients was 40 years (range 21-63) and the mean follow up period was 16.2 months. Laparoscopic cardiomyotomy took on average 111 minutes (range 75-120). Mean inpatient stay was 3.1 days (range 2-6 days) and the majority of patients were admitted the day prior to surgery. More recently patients have been admitted on the morning of surgery with further reduction in hospital stay.

One mucosal perforation occurred as a result of the procedure. This was noted intraoperatively and sutured laparoscopically with 2/0 Vicryl (Polyglactin, Ethicon, New Jersey USA) suture. Postoperatively a non ionic contrast swallow revealed that the perforation was sealed and the patient discharge on the 4<sup>th</sup> postoperative day. There was no other morbidity, no mortality and no patient required conversion from laparoscopic to open procedure. At follow up 2 patients (11%) were taking proton pump inhibitors for symptoms of acid reflux and 1 patient had had an gastroscopy revealing reflux oesophagitis. BMI was significantly increased from preoperative mean of 22.3 to 25.8 kg/m<sup>2</sup>. ( $P < 0.05$ ) No patient had required further intervention (e.g. pneumatic dilatation or injection of botulinum toxin) for recurrent dysphagia.

## DYSPHAGIA SCORES

The mean dysphagia score was significantly improved. 7.5 (range 2.5-15) to 33.9 (range 18.5-45) at review ( $p < 0.005$ ) [figure 5] 1 patient from the 18 (5.5%) had an unsatisfactory response with a dysphagia score rising only from 8.5 to 18.5 and recurrent symptoms. A gastroscopy revealed reflux oesophagitis and he is currently being managed with acid suppression.

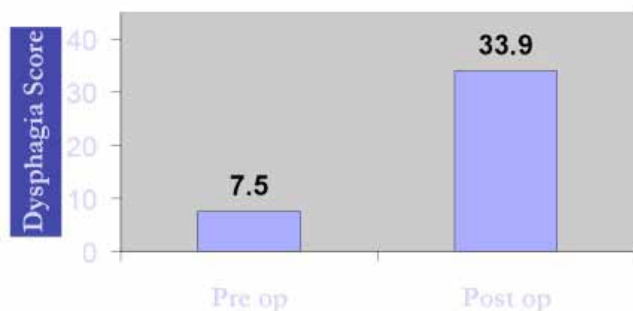


Fig 5. Dysphagia Score pre and post operatively ( $p < 0.005$ )

## OTHER SYMPTOMS

There was a significant improvement in regurgitation, sleep disturbance, epigastric pain and odynophagia. (Table 2) There was no significant difference in the severity of heartburn. The effect on regurgitation appeared to be most marked, with pre operative scores improving from a mean of 3.8 to 0.8 post operatively.

TABLE 2

Pre and Postoperative Symptom scoring

Symptom	Pre op score (0-4)	Post op score (0-4)	
Regurgitation	3.8	0.8	$P < 0.005$
Odynophagia	2.5	0.7	$P < 0.05$
Sleep Disturbance	2.7	0.6	$P < 0.05$
Epigastric pain	1.5	0.5	$P < 0.05$
Heartburn	1.6	0.8	$P > 0.05$

## DISCUSSION

The most important outcome for the patient with achalasia is relief of dysphagia. Our results indicate that laparoscopic cardiomyotomy is an effective treatment for achalasia and are in keeping with the large series in the published literature.<sup>8, 10</sup> Our study is limited by its small size, the use of telephone to administer the questionnaire and the fact that a single investigator collected and collated the data. Previous studies have suggested that those patients with a high ( $> 35$ mmHg) LOS pressure benefit much more from myotomy than those with pressures lower than this. Indeed, preoperative LOS pressure has been shown clearly to be the single strongest predictor for successful outcome.<sup>8</sup> This was not specifically examined for in our study. Age, sex and a history of previous pneumatic dilatation or Botulinum Toxin injection are not correlated with success or failure.<sup>8</sup>

Evidence is accumulating that laparoscopic cardiomyotomy produces better results in the long term than pneumatic dilatation (PD). One recently reported randomized controlled trial (RCT) has addressed the issue<sup>11</sup>. Kostic et al found that at 12 months PD produced more treatment failures and that this trend increased with time. In addition, Vela and colleagues compared the long term efficacy of PD with that of laparoscopic cardiomyotomy.<sup>7</sup> They defined success in the long term as freedom from further interventions. At 6 years freedom from intervention was 28% in the single pneumatic dilatation group versus 57% in the laparoscopic cardiomyotomy patients. Indeed many patients from the PD group with more severe disease crossed over to cardiomyotomy, otherwise the difference may have been even greater. Cardiomyotomy has also previously been shown to be superior to PD in the long term.<sup>12</sup> There are no RCTs comparing the traditional transabdominal or transthoracic approaches with the laparoscopic procedure. There is good evidence from a well designed RCT that the addition of a Dor fundoplication reduces the risk of pathological gastro-oesophageal reflux without compromising relief of dysphagia. Richards and colleagues<sup>13</sup> found that without a fundoplication, the incidence of pathological reflux ( $pH < 4$  for more than 4.2% of a 24 hour period) was 47%. The addition of an anterior 180 degree Dor fundoplication reduced this to 9% without any effect on post operative dysphagia or LOS pressure reduction.

Treatment failures following laparoscopic cardiomyotomy are most commonly related to inadequate myotomy, and occur more frequently on the "learning curve" phase of a surgeons training. After this, rates of failure and complication are remarkably similar between surgeons and hospitals.<sup>14</sup> Rates

of recurrent dysphagia within one year are commonly 8-10%. Those patients with an already markedly dilated or “sigmoid” oesophagus often have recurrent symptoms following surgery. This group may be identified preoperatively via OGD and a (usually) lower LOS pressure. These patients may eventually require oesophagectomy.

### CONCLUSIONS

Accumulating evidence supports early aggressive therapy of achalasia.

Laparoscopic cardiomyotomy is a safe, highly effective and minimally invasive treatment and many authorities consider it the first line treatment.<sup>8</sup>

The authors have no conflict of interest to declare.

### REFERENCES

1. Vaezi MF, Richter JE. Diagnosis and management of achalasia. *Am J Gastroenterol.* 1999;**94**(12):3406-12.
2. Mayberry JF, Rhodes J; Achalasia in the city of Cardiff from 1926 to 1977. *Digestion.* 1980;**20**(4):248-52.
3. Mayberry JF, Atkinson M; Studies of incidence and prevalence of achalasia in the Nottingham area. *Q J Med.* 1985;**56**(220):451-6.
4. Gonlachanvit S, Fisher RS. Diagnostic modalities for achalasia. *Gastrointest Endosc Clin N Am.* 2001;**11**(2):293-310.
5. Khajanchee YS, Kanneganti S. Laparoscopic Heller myotomy with Toupet fundoplication: outcomes predictors in 121 consecutive patients. *Arch Surg.* 2005;**140**(9):827-34.
6. Bortolotti M, Mari C, Lopilato C, Porrazzo G, Miglioli M. Effects of sildenafil on esophageal motility of patients with idiopathic achalasia. *Gastroenterology.* 2000;**118**(2):253-7
7. Vela M, Richter JE, Khandwala F, Blackstone EH, Wachsberger D, Baker ME, *et al.* The long term efficacy of pneumatic dilatation and Heller myotomy for the treatment of achalasia. *Clin Gastroenterol Hepatol.* 2006;**4**(5):580-7
8. Torquati A, Richards WO, Holzman MD. Laparoscopic myotomy for achalasia. *Ann Surg.* 2006;**243**(5):587-93
9. Watson DI, Jamieson GG, Devitt PG. A prospective randomized trial of laparoscopic Nissen fundoplication with anterior vs posterior hiatal repair. *Arch Surg.* 2001;**136**(7):745-51
10. Patti MG, Pelligrini CA, Horgan S, Arcerito M, Omelanczuk P, Tamburini A, *et al.* Minimally invasive surgery for achalasia. an 8 year experience with 168 patients. *Ann Surg.* 1999;**230**(4):587-94
11. Kostic S, Kjellin A, Ruth M, Lonroth H, Johnsson E, Andersson M, *et al.* Pneumatic Dilatation or Laparoscopic Cardiomyotomy in the management of newly diagnosed idiopathic achalasia. *World J Surg.* 2007;**31**:470-8
12. Csendes A, Braghetto I, Henriquez A, Cortes C. Late results of a prospective randomised study comparing forceful dilatation and oesophagomyotomy in patients with achalasia. *Gut.* 1989;**30**(3):299-304
13. Richards WO, Torquati A, Holzman MD. Heller myotomy versus Heller myotomy with Dor fundoplication for achalasia. *Ann Surg.* 2004;**240**(3):405-15.
14. Zaninotto G, Costantini M, Portale G, Battaglia G, Molena D, Carta A. Etiology, diagnosis and treatment of failures after laparoscopic Heller myotomy for achalasia. *Ann Surg.* 2002;**235**(2):186-92