

Richard Sydney Allison (1899–1978)

President of the Ulster Medical Society

1969–70

Presidential Opening Address

Ulster Medical Society
23rd October 1969

THE PARIETAL LOBES: CLINICAL AND PATHOLOGICAL ASPECTS OF THEIR DYSFUNCTION

“The middle third of the cerebral hemispheres, strategically situated between the frontal, occipital and temporal lobes, is closely related in function to each of these regions of the brain. Partly as a result of this, a greater variety of clinical manifestations is likely to result from disease of the parietal lobe than from disturbance of any other part of the hemispheres. It must be emphasised, however, that these phenomena require special techniques for their elicitation, otherwise they may be easily overlooked or discounted in a routine clinical examination”.

SOME years ago Dr. Hurwitz and I had the chance opportunity of visiting an alligator farm in Florida. The monsters were kept in huge open pens and presented a lifeless appearance as they lay sprawled, partly on top of each other, in the hot sun. There was no blinking of their wide-open, staring eyes, no evidence of respiratory movements in their flanks - they might have been dummies, made out of pasteboard.

Two irresponsible, young servicemen, spectators of the scene as we were, after vainly trying to stir the creatures into activity by waving pocket handkerchiefs in front of their snouts and clapping their hands, poked a stick into one of them. The sensation produced must have been one more of increased pressure than of pain, but the result was dramatic for instantly the movement made in response to the stimulus had communicated itself to the other 20-30 reptiles in the pen so that they were transformed into one writhing, fearsome melee of thrashing tails and snapping jaws. And it was not until this welter of mass movement had subsided that the creatures lapsed once more into their natural posture of immobility.

It was a striking demonstration of the part played by proprioceptive sensory stimuli in initiating



movement. In man, as in the reptiles, awareness of posture and of the different body parts is effected involuntarily through the sensory flow emanating from spindles and other deeply-placed end organs in tendons, muscles and joints. These, as we know, are conveyed by the posterior columns of the cord to the lower brain stem where they excite appropriate motor responses through the nuclei of the extrapyramidal system. Thus, at any given moment in time, posture is determined not by deliberate thought, but automatically. Only novel or confusing combinations of stimuli are transmitted to the highest sensory level in the parietal cortex, there to be synthesized and identified after comparison with the other sensory data already stored in the brain from past experience.

And this is the probable reason why, in man, pathological disturbances affecting the parietal region give rise to so little obvious effects as compared to those involving the motor cortex, the speech area in the fronto-temporal region of the dominant hemisphere, and the occipital lobes. The probability is that under terrestrial conditions the functions of the

Richard Sydney Allison



Fig 1. By kind permission of National Aeronautic and Space Administration

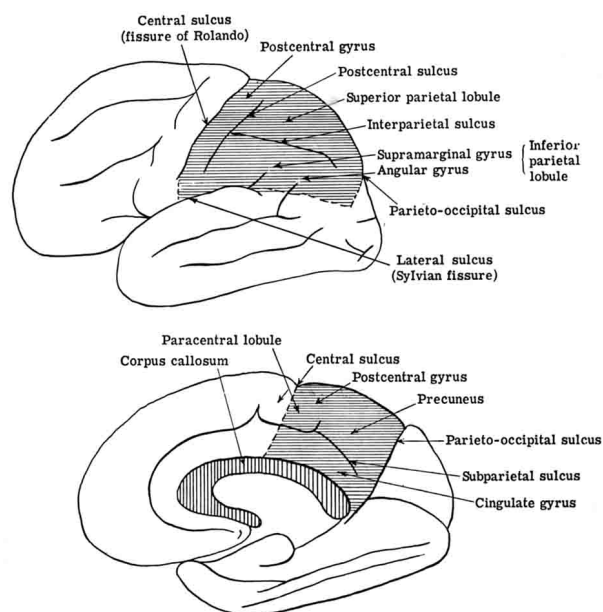
parietal cortex are largely dormant and its potentialities still under-developed, but it is conceivable in this year, with the arrival of the first human beings on the surface of the moon (Fig. 1), that we may be entering upon a new era of cerebral physiology. Apparently the astronauts found that even the act of moving the head on the neck was difficult and they were uncertain as to the relation of their feet to the ground. As Edwin Aldrin said: "... you have to take 2-3 paces before you can be sure your feet are underneath you." In walking, as was seen on television, they adopted a slow, prancing type of gait.

Thus, just as the capacity for speech and language developed in the human brain from the need for men to communicate with one another, so it is possible in the future that the parietal lobes may undergo further physiological development in respect to the new problem with which man will be confronted by his journeys into outer space, more frequent experiences of bodily weightlessness and the need to adjust his

fixed, terrestrial, proprioceptive mechanism to the changing effects of gravitation on other planets.

This is the first reason – albeit a purely hypothetical one – which has prompted me to choose the parietal region as subject for the Presidential Address this year. I hope it may have some interest for the members of this old-established society, which has ever been representative of most if not all the disciplines in medicine and surgery.

The parietal lobes are an artificial or man-made convention; as it has been said "a topographic convenience pegged out upon the surface of the brain." Until the beginning of the nineteenth century the cerebral cortex was not partitioned into lobes. The term "parietal" only came into usage about 1850, after Burdach and other anatomists began to speak of lobes and the tendency was to correlate the different regions of the cortex with the skull bones overlying them. Figures 2 and 3 illustrate the extent of the parietal lobe: on the lateral surface it is roughly quadrilateral in shape; anteriorly the central sulcus forms its boundary, as does the lateral sulcus inferiorly; the posterior margin is formed by an arbitrary line drawn downwards and slightly forward from its parietooccipital sulcus to its junction with the line of the lateral sulcus as extended posteriorly. The interparietal sulcus divides the superior parietal



Figs. 2 & 3. The lateral (above) and the mesial (below) aspect of the parietal lobe are shown by horizontal shading.

(Reproduced by kind permission of Dr. E. O. Jewesbury, London, from "Handbook of Clinical Neurology", Vol. 2; P. J. Vinken and G. W. Bruyn, Eds., North-Holland Publishing Co., Amsterdam, 1969).

Richard Sydney Allison

lobule from the inferior, and other features on the lateral surface are the post-central gyrus, the angular and supramarginal gyri. On the medial side the parieto-occipital sulcus marks its posterior margin as does the imaginary extension of the central sulcus over the paracentral lobule, behind which is the precuneus. Part of the subjacent cingulate gyrus is also included.

A second reason for choosing the parietal area is because of the many interesting syndromes to which disorders of its blood supply can give rise. Placed as it is at one of the chief watersheds between the opposing streams of the carotid and basilar-vertebral systems, the parietal cortex and its underlying white matter may be likened geographically to a tableland or sort of "high veldt". Blood supply on its lateral surface is derived from the third and fourth terminal branches of the middle cerebral artery, which ends in the artery to the angular gyrus. The medial part of the lobe is supplied by branches of the anterior and posterior cerebral arteries. A not uncommon anomaly of the circle of Willis is a rudimentary or absent posterior cerebral artery on one side. This may not matter in health but, when occlusion has occurred in one or other of the carotid or vertebral arteries so that cerebral circulatory efficiency is being maintained by three main trunks only, any additional disadvantage makes it all the more likely that the parietal area will be the first part of the cortex to suffer the consequence of ischaemia.

The concept of cerebral circulatory insufficiency has only been developed in the past fifteen years and with it has come realization that additional occlusion of main vessels is not always necessary to provoke it. Cerebral circulatory insufficiency can be induced by such differing aetiological factors as hypoxia, hyperglycaemia, hypoglycaemia, cervical spondylosis, the onset of cardiac arrhythmia to name only a few of its many precipitating causes. When cerebral ischaemia is prolonged, areas of necrosis (ischaemic infarction) result, but there are plentiful anastomotic connections between the four major vessels supplying the brain, and their intracranial branches also anastomose freely before entering the brain substance. In case of blocking of one middle cerebral artery, a collateral circulation can be established by opening up of communications between lepto-meningeal branches and terminal branches of the anterior and posterior cerebral arteries so that the territory may again be adequately supplied with blood. Time, however, is an indispensable factor if an efficient collateral circulation is to be established. Ross Russell and Symon have shown in experimental

work with baboons that, when one carotid is ligated, there is a marked fall of intracranial perfusion pressure. The same occurs after the second carotid and, following that, a vertebral artery is ligated. But, if 6 weeks to 3 months are allowed to elapse between the ligation of each main vessel, when all three are tied, the animal is left with an intracranial circulatory pressure, stabilized at about 50 per cent of which it was in the intact animal.

The clinical implications to be drawn from these observations are especially relevant to man because the sudden onset of mental confusion may be the only obvious expression of cerebral circulatory failure at the parietal watershed. There will be no hemiplegia, no aphasia, none indeed of the classic signposts upon which we are accustomed to rely in making the diagnosis of an acute cerebral vascular lesion. Mental symptoms predominate and the mistake is easily made of assuming that these are of purely psychological origin, if not due to some toxic cause such as drugs. The parietal region is often spoken of as one of the "silent" regions of the brain – silent, that is, because lesions of it give rise to no gross physical signs – but, if steps be taken to examine such patients closely, evidence will usually be found that intellectual function has been impaired. This is my second point: to draw attention to the frequency, in middle and later life, of minor vascular disturbances affecting this region, and to remind you that the clinical effects are often reversible. When a patient recovers his former mental health, therefore, it does not follow, *ipso facto*, that this can be attributed to the "treatment" given.

The third point is one which will also be familiar to the psychiatrist: the frequency with which the primary, cerebral cortical atrophies, e.g., Alzheimer and Pick's diseases, can be simulated by brain tumours, and especially, meningiomata. These tumours are relatively frequent in later life and are most eminently suitable for operation, but they can, and often do, grow quietly in the parietal region and remain unsuspected for years. The same is true of chronic subdural haematoma, although here a shorter history is usually obtained and there are recurring periods of drowsiness and other signs of fluctuating intracranial pressure to guide one.

The older textbooks stressed the tendency of meningiomata, when situated on the convexity of the hemisphere, to cause fits. But, if fits occur with parietal tumours, they are usually so transient or so psychical in their content as to pass unnoticed, and in none of my own personal cases were fits a prominent feature although, as in presenile dementia, gross impairment of memory was often seen. Curious

Richard Sydney Allison

aurae, described as “jamais vue” and “deja vue” can also occur with parietal lesions, and it is probable that specific impairment of topographic memory is related to disturbances of function in this region.

One recognizes the enormous strides which have been made in the diagnosis of intracranial tumours and focal vascular lesions by instrumental means: echoencephalography, studies of cerebral circulation time, and brain scanning with isotopes. These tests can be done in a single day and have an even more important advantage over lumbar encephalography and angiography in that they give rise to no ill-effects to the patient. Dr. Swallow has recently conducted a trial to appraise their diagnostic value in 107 selected patients – 67 suspected of harbouring an intracranial tumour, 17 thought to have cerebral vascular disease, and 11 suspected of presenile dementia. In 83 out of the 107 cases, or over 77 per cent, a correct diagnosis was reached through their use.

There is, of course, the expense of these refined methods of investigation to be considered but the clinician need not despair; a place still exists for simple, bedside techniques of examination, which cost only time and patience. So I propose to devote the remainder of this hour to consideration of the signs and symptoms one may expect to find in patients with parietal disease. The clinical approach demands some appreciation of both physiological and psychological mechanisms because in many respects the symptoms belong to that border-line area or “No-man’s Land” which lies between neurology and psychiatry. It is, however, a fascinating field which any interested doctor may explore with profit and with only his senses to guide him. Far from contracting, as has happened in some other clinical fields in which instrumental methods are now taking precedence over purely clinical methods, the field of clinical neuropsychology is expanding, many aspects of it still awaiting elucidation.

First it must be emphasized that the subjects of organic brain disease are more suggestible than are normal, healthy persons. Their responses to tests vary from day to day and are influenced to some extent by the degree of rapport it is possible to establish with them. They tend to conceal rather than to flaunt their disabilities and, especially in parietal disease, have difficulty in grasping what is required of them. This is not due to stupidity or lack of co-operation on their part but to the peculiarities of their mental disturbances.

For many years in the approach to such patients, I have abandoned traditional methods of case-taking and simply invited the patient to tell me about himself

or to say in what direction his difficulties lie. He is encouraged to talk, leading questions being avoided, and his spontaneous utterances, lucid or garbled, brief or long, as the case may be, are taken down as far as possible verbatim; and during the recital as much attention is paid to his behaviour as to what he actually says. The notes are then supplemented by responsible relatives and friends upon whom one relies for details of past illnesses, the work record, family history, possible exciting causes and duration of symptoms.

Physical Signs in Focal Parietal Disease

A. Sensory Disabilities

- (1) Impaired joint-position sense in fingers.
- (2) Loss or impairment of two-point discrimination.
- (3) Defective tactile localization of stimuli.
- (4) Sensory neglect or “inattention”.
- (5) Astereognosis.

B. Motor Disabilities

- (1) Some degree of inco-ordination.
- (2) Diminished muscular resistance to passive stretching.
- (3) Muscular wasting.
- (4) Poverty of voluntary movements.
- (5) Manual dyspraxia.

Sensory Disabilities in Parietal Disease

The sensory disabilities were first clearly defined in 1911 by Head and Holmes and more recently have been reviewed very fully by Macdonald Critchley. Crude or common sensation is unaffected, the patient being capable of appreciating touch, pain, temperature changes, vibration and the position of joints, like any normal person. This is the general belief, but it has been my experience, when sufficient care is taken, that *defects in position sense in the distal joints of the fingers and toes*, on the side contralateral to the lesion, can often be demonstrated. Such tests involve the making of judgements and it is important, I think, to have a trial first with the patient’s eyes open so that he can both watch and feel passive movements being made and demonstrate by his answers, when the joint is moved passively “up” or “down” that he comprehends what is expected of him and that any hesitancy he shows is not due to an associated expressive speech difficulty. The interphalangeal or terminal phalangeal joints are selected and, with the rest of the limb immobilized, passive movements are made abruptly, a pause being given between each test, during which the joint is held still and the patient gives his answer. In patients with more obvious expressive aphasia, spoken

Richard Sydney Allison

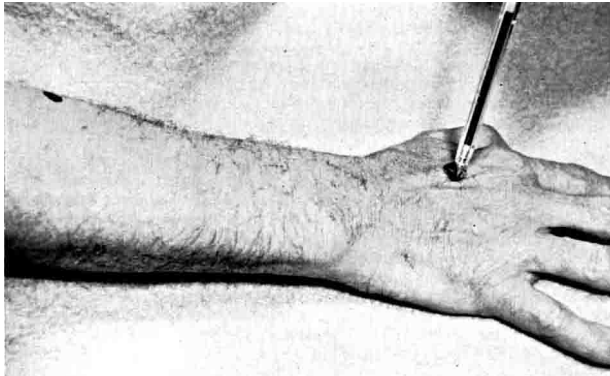


Fig. 4. Tactile localisation. Keeping his eyes closed, the patient is told to concentrate on where he feels the pencil touching him. The point of the pencil is held in position for a few seconds and then withdrawn.

answers should not be sought but the subject directed instead to copy the direction of the movements being made by the examiner with the thumb of his disengaged hand.

Loss or impairment of two-point discrimination over the finger pads on the side contralateral to the lesion is one of the most reliable signs of parietal disease. One can use a standard aesthesiometer, but pointed wooden sticks will do very well. Less important than the actual measurement of the distance apart two tactile stimuli must be placed before they are perceived separately is the repeated demonstration that this difference is much greater on one side than it is on the other, e.g., 1-2 mms. on the right finger pads as compared to 7-10 mms. on the left.

Another valuable sign of parietal dysfunction which is not tested for as often as it should be is *defective tactile localization*. With the patient's arms extended, wrists pronated and completely relaxed, points on the skin over the palms of the hands, forearms and arms are touched with the point of a marking pencil. The point should be retained in position for a few seconds before it is withdrawn and the patient then invited to indicate with his finger the place where he has been touched (Figs. 4 and 5). As before, testing is done first with his eyes open and then closed. The points he indicates are marked with a cross and the distances between the actual and judged sites compared on the two sides; only big differences, e.g., 2 centimetres or more, over the back of the hand or 5-10 centimetres over the forearm, are significant. Trifling differences can be ignored. The whole point of the test is to show a consistent discrepancy between the two sides.

In some instances of parietal disease, position

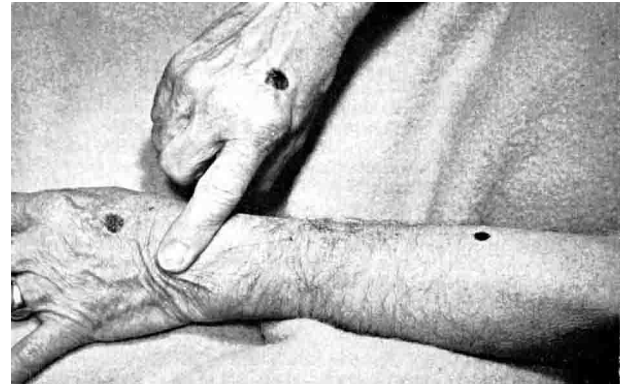

Fig. 5. Tactile localisation. The patient then points with the forefinger of his other hand to the supposed point of touch. The distance between the actual and supposed points of touch are measured and compared on the two upper extremities.

sense in the contralateral limbs is so defective, especially in the upper limb, that the patient has difficulty, with the eyes closed, in finding the affected limb in space when it is held away from the body and he is told to grasp the thumb with his other hand. He gropes about in space until the hand comes into contact with some part of the limb, usually in the region of the elbow, after which he works his way down with his hand until he comes to the thumb.

When the above signs can be elicited they provide strong evidence for a parietal lesion. But, as always in making a diagnosis of organic brain disease on the basis of subjective findings, confirmatory proof is required in the patient's behaviour of some sensory disability and this is usually forthcoming when tactile or painful stimuli are applied simultaneously to the two sides (Fig. 6). Typical is the finding that, although single stimuli are perceived on either side, when they

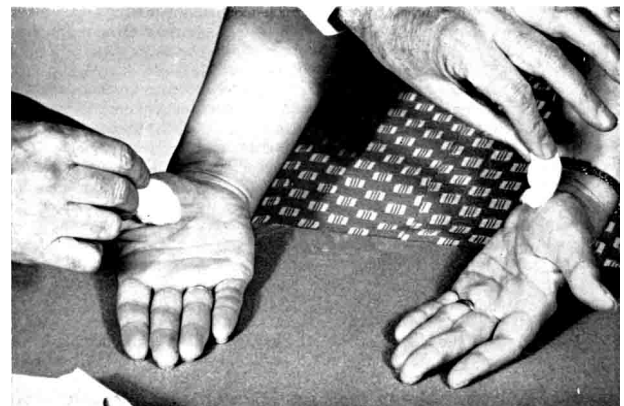


Fig. 6. Application of simultaneous tactile stimuli to the same points on both sides for demonstration of sensory neglect or inattention. (Actually on the illustration the points are not quite identical. Coarse stimuli are being applied purposefully).

Richard Sydney Allison

are applied simultaneously the stimulus over the affected side is ignored. Varying the intensity of the stimulus does not affect this result for a patient may repeatedly deny a pin prick applied to his affected arm when a light touch is made simultaneously to the same point on the opposite limb. The same applies to the face, but, to a lesser extent to the trunk where the phenomenon is usually not demonstrable except in association with gross sensory loss, when it obviously ceases to have significance *per se*.

Sensory inattention or neglect affects a subject's day to day activities in different and often bizarre ways: One man, who later was successfully operated on for a large, right, parietal meningioma, has been a semi-invalid for some years. Following a transient spell of weakness in the left arm, attributed to a minor vascular accident, he found that although power had returned to the limb it did not feel normal. And one day, rummaging about in a drawer for some object, when he found it and went to close the drawer, he left his arm in it, injury resulting through its not being automatically withdrawn along with its fellow. Another instance which may be cited had even more misleading consequences :

The patient, the foreman of a gang of shipwrights in Harland & Wolff's, aged 58, had been admitted to hospital under the suspicion that he was suffering from syringomyelia. This was because there was an extensive third-degree burn (? from a cigarette) on the back of his left hand, which he could not account for. His relatives were more concerned at the confusion of mind he had shown for some weeks and which had reached its climax one night when he appeared in the street, clad only in his night attire.

General and neurological examination was negative. When tested with single pin pricks and touches he responded naturally although not so promptly over the left arm as on the right. There was no dissociated sensory loss, but when pin pricks were applied to the two sides simultaneously, he invariably ignored the stimulus on the left.

His mood was euphoric and talk free and uninhibited. There was defective memory for recent events and he was disorientated in time, but not for place or for persons.

Despite the evidence of dementia it was felt that the repeated demonstration of unilateral sensory inattention justified further action and, thanks to Mr. Gleadhill, a ventriculogram was done: it showed a chronic subdural haematoma lying over the right parietal cortex. This was evacuated, the sensory inattention on the left arm disappeared, and the patient returned to his work in the Yard, although still

exhibiting some signs of cerebral deterioration.

Astereognosis. Failure to recognize by touch alone the nature of an object is probably the best known and most widely tested sign in parietal disease. Absolute failure, however, usually denotes the co-existence of some crude sensory loss as occurs, for example, in disseminated or multiple sclerosis, when there is a plaque in the cervical cord, lying astride the posterior root entry zone coming from the ipsilateral upper extremity. The parietal patient's common sensation is virtually intact. His disability may be compared to that of a man who, whilst fully capable of selecting a shilling or ten shilling piece from among other loose change in his pocket, would be at a loss if required to identify the coins of any other system of currency. All such acts of identification depend on past experience and upon the integrity of the storage system for such memories within the brain and of the connecting neutral pathways.

Stereognostic disabilities, of course, only have significance in indicating a focal parietal lesion when it can be demonstrated that they are present only on the contralateral side. Varying degrees of bilateral dystereognosis are in keeping with global, cerebral cortical affections, or they may be due to an expressive speech defect with particular naming difficulty. So as before, when in doubt, the patient should first be shown the objects with which he is to be tested and invited to name them. A duplicate set of the same should be left exposed to view whilst, with his gaze averted, the same objects in turn are placed in the hand to be tested; all he has to do then is to point with the free hand to its fellow on the table before him.

Another method is to observe his performance when identical objects are placed simultaneously in his upturned palms. Thus, if two-shilling pieces are used, the object lying in the unaffected hand is identified promptly by the patient's pronating his wrist and bringing the coin swiftly into apposition between the pads of the thumb and forefinger or middle finger. One or two stroking movements are then made and he announces what it is. Meanwhile, on the affected side, no notice may be taken of the coin until his attention is drawn to it and then, if he pronates the wrist, his attempts to manipulate it into apposition with the finger pads are clumsily effected, the fingers bunching together and the coin being held loosely between three or four of them with one of its edges protruding, if it does not drop to the ground. These dyspraxic features are frequent accompaniments of dystereognosis although, when the examiner

Richard Sydney Allison

himself deftly manipulates the patient's fingers over an object, reproducing the same motor pattern as is employed in identification, the subject of parietal disease will still be unable to say what the object is.

A feature common to all such patients is their tendency to guess at the nature of objects, without first submitting them to careful tactile scrutiny, or to persevere, naming the first one or two objects correctly, e.g., a toothbrush, cork, and then when a comb is placed in their hands, to declare that it is a toothbrush. This reflects the natural mode of perception in health whereby it is necessary only to recognize one or other distinctive feature of an object to enable an appropriate "gestalt"¹ to be formed of the whole. All brain-damaged subjects are defective in their ability to separate the relevant from the irrelevant; to distinguish between the central feature in a set and background objects. But this does not mean they are incapable of re-learning former skills. Provided its underlying pathological cause is no longer active, this can be effected to some extent with the help of an occupational therapist who is prepared to devote her time and patience to instructing the patient not to guess but to fall back on the more tedious method of apperception, that is, the amassing of as much information as possible of the different qualities of an object before coming to a conclusion as to its nature.

This view was supported by a case, seen some years ago, in which there was a prolonged follow-up period. He was an intelligent man in his late fifties who had sustained a left cerebral thrombosis, causing hemiparesis and some receptive and expressive dysphasia. After three months these signs disappeared and, although there was no gross sensory impairment, he was left with a residual, severe degree of dystereognosis in the right hand.

Limiting the number of objects and selecting only such as were big and had many distinctive qualities – e.g., a pair of scissors, glove, toothbrush, pipe, comb – attempts were made to familiarize him with them by repeated usage and testing. But, despite all efforts, the tendency to guess wildly or to persevere went on until the patient became exasperated by his repeated failures. Smooth-surfaced, plane and spherical wooden shapes were then prepared and presented to him, his attention being drawn to the three edges possessed by the triangle, the four by the square and the absence of angles in the circle; and, within 1-2 weeks he was making swift progress in their recognition, ultimately





¹ Gestalt (German)=form, shape, figure. The gestalt school of psychology's views succeeded those of older psychologists who held that perception occurred chiefly by transcortical association: A+B+C+D etc., so-called "apperception".

passing on to more elaborate articles such as those which had first been used. It was also observed that, whereas before he had made little or no attempt to bring his right hand into use for bimanual tasks, he was now employing the affected arm more naturally. Fig. 7 and Fig. 8 are taken from samples of his answers whilst undergoing tests.

Fig. 7. *Dystereognosis of Right Hand following Cerebral Thrombosis.*
(A HANDKERCHIEF)

- Q. What shape is it ?
A. "It does not seem to have any shape."
Q. Is it hard ?
A. "No, it is soft; I can crush it with my fingers."
Q. Is it rough to the feel ?
A. "No, it's smooth."
Q. Is it heavy ?
A. "No, it's light."
Q. What do you think it could be ? It is something you use every day; it has no shape and is soft, smooth and light.
A. "... it could be a piece of cloth."
Q. Yes, that's very good. A piece of cloth for doing what ?
A. "Well, you might wash you face with it."
Q. Are there any other uses for a piece of cloth, that is soft and that you can crush, and has no shape ?
A. "... (suddenly) it could be a handkerchief."

Fig. 8. *Dystereognosis. Limited Number of Test Objects.*

-  = "That's the square piece of wood because it has four corners and is flat."
 = "That's the ball . . . I can't squeeze it."
Examiner: Is it flat ?
Patient: "No, it's not flat, it's round and the full of my hand."
 = "There's three sides to it . . . I'm not sure about it . . . it's smooth and flat . . . it's a triangle."
 = "That's flat, round and smooth . . . it's the circle."

Motor Disabilities in Parietal Disease

Provided the parietal lesion does not encroach upon or compress neighbouring cortical and subcortical motor areas, there is no paralysis. But nearly always it is possible to demonstrate some

Richard Sydney Allison

degree of inco-ordination together with diminished muscular resistance to passive movements in the limbs on the side opposite to the lesion. Muscular wasting, or rather some loss of substance in muscle, is seen occasionally in the small muscles of the hand and in the shoulder girdle, but its absence should not invalidate the diagnosis of parietal disease for it is by no means always demonstrable. By far the most common expression of motor disability is hypokinesia or poverty of voluntary movement, the arm remaining idle in common activities, which would normally require the use of both hands (Fig. 9). The motor dyspraxia often seen in patients with stereognostic defects has already been referred to.



Fig. 9. Motor neglect. Matches are scattered on the table before the patient and he is told to pick them up as quickly as possible. This man had a right posterior parietal tumour and although there was no evidence of contralateral weakness he used only his right hand to replace the matches in the box.

Intellectual Defects in Parietal Disease

1. Dystereognosis.
2. Visual Spatial Disorientation and Simultanagnosia.
3. Constructional Apraxia and Picture Agnosia.²
4. Disturbances of the body image or schema: autotopagnosia.²
5. The Gerstmann syndrome: finger agnosia, agraphia, acalculia and right-left disorientation.

Of specific intellectual defects to which focal parietal lesions may give rise disturbances of the stereognostic sense have already been considered. *Visual spatial disorientation and simultanagnosia* is a rare combination which is seen only when there are bilaterally placed lesions of the parieto-occipital

² Denotes that these symptoms are often found in association with general clouding of consciousness and tend to disappear as "full" consciousness is regained. They have only localising, diagnostic value when they persist or occur at a time when a patient shows no other signs of clouding of consciousness.




Fig. 10. Balint's syndrome. Shaking hands. The patient, John G., aged 33 years, an electrician, has his back to the door and is being greeted by Dr. Graham White.

cortex. In Balint's original case bilateral softening was found. Holmes' cases occurred in soldiers with bullet wounds of the head. In a case of Hécaen and Ajuriaguerra a bilateral parieto-occipital astrocytoma was present and in another case, seen more recently at Claremont Street Hospital by Allison, Hurwitz and others the symptoms followed decompression for an Arnold-Chiari type of malformation.

During the operation there had been a profound fall of blood pressure and this and anoxia were thought to be the cause. No anatomical confirmation of the site of the lesion was possible, but the visual field defects suggested biparieto-occipital lesions. This patient still attends hospital regularly and has succeeded in making a fair amount of adjustment to his disabilities.

Originally his visual spatial disorientation made it impossible for him to relate the position of objects to himself in space. In groping his way across a room, he would bump into things, not because he could not see them but because he could not tell how far away or how near they were. He could not shake hands without first groping at random for the other person's proffered hand (Fig. 10); sit down on a chair unaided, or pour liquid from a bottle into a glass (Fig. 11). When a series of objects was set on a table before him he was unable to indicate by sight which were nearer and which further away, although he had no such difficulty in locating the site and relative distance away of sounds. Now after 4½ years, his concentration on visual clues in moving about is still very obvious but he can reach out correctly towards objects, shake hands naturally, and sit down on a

Richard Sydney Allison



Fig. 11. *Balint's syndrome. Pouring liquid from bottle into a glass (6 months after onset symptoms).*

bench unaided.

His other great defect – inability to perceive more than one object at a time (simultanagnosia) – was very pronounced at the start. Wandering eye movements and locking of the eyeballs in fixation on an object were seen only in the first six months of the recovery period but defective scanning movements of the eyes persisted much longer. He could read single words with ease, provided they were shown one at a time against a plain background, and he understood their meaning, but he was totally at a loss to comprehend the printed instruction: “Put out your tongue!” although if the words were shown to him separately and consecutively they made sense and he complied.



Fig. 12. *Balint's syndrome. Patient reading with aid of wooden frame.*

To compensate for the reading difficulty it was necessary to improvise and he was provided with a wooden frame, especially constructed for the purpose. The frame, 18 inches square, had raised wooden strips as sides and was crossed horizontally at regular intervals by similar wooden strips.

Between these strips was inserted simple reading material, for example, newspaper headlines, transcribed in bold script, the words spaced at first not less than 2 cms. apart and with a pencilled line between each word. The patient had to place his index finger on the topmost horizontal strip (that is, top left corner of frame), and direct his gaze to his finger and thence to the word above it. When he came to the end of each line he was taught to guide his finger back again along the raised strip to the starting point where it met the edge of the frame, and then to lower it down the frame until he could feel the next strip below. Reading improved as he became familiar with the device and after two years he passed

Richard Sydney Allison

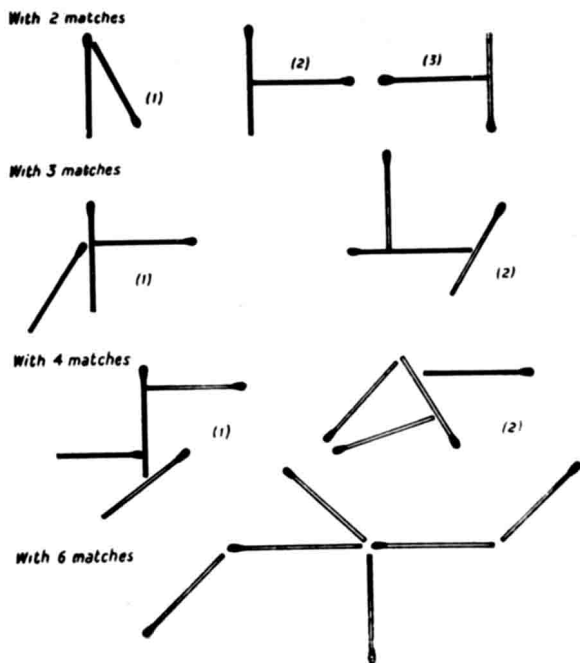


Fig. 13. Constructional apraxia. Examples of simple designs made with match sticks, used for testing.

on to the use of mechanically run typescript on a drum, with the words set out in bold type and 5 mms. apart, the patient rotating the drum at his own speed. At the end of 4 years, he could read aloud Schonell's Simple Prose Reading Test, "My Dog", almost perfectly and with fair comprehension (Fig. 12).

Constructional Apraxia, as its name implies, refers to inability or defective ability to bring together into appropriate relationships with each other the component parts of a thing so as to form a whole. The act of laying a table for dinner, cutting out a dress from paper patterns or assembling the parts of a mechanical carpet sweeper are examples of constructional activities common to women just as are working in a machine shop from blueprints, wiring up an electrical circuit or erecting scaffolding equivalent tasks for men. Constructional apraxia is a common and often early symptom of generalised brain disturbance. Like picture agnosia, its perceptual counterpart, in which the different objects in a picture are recognised, but its meaning not understood, it is probably representative of failure to formulate appropriate gestalts. If looked for specially it can be observed in previously healthy subjects recovering from exposure to anoxia, after electric convulsion therapy and in epileptics regaining consciousness after a fit. It is seen too, in the early stages of dementia before the relentless advance of

cerebral cortical atrophy has reduced its victim to vegetativeness. With purely focal brain lesions causing no disturbance of general consciousness, it is much less common. However, its frequent association with one or more of the features of the Gerstmann syndrome has prompted the belief that parietal disease is especially prone to induce the development of constructional difficulties and I have seen two patients, both with tumours involving the non-dominant hemisphere, in whom it was one of the earliest defects noted, the constructional dyspraxia being demonstrable for some time before their condition worsened with signs of general and increasing clouding of consciousness.

The most convenient and reliable way of testing for it is by the use of match sticks or Kohs' blocks. In the former method one assembles 2-3 matches or more in a geometric pattern and invites the patient to copy the design (Fig. 13).

For purely clinical diagnostic purposes it is not a matter of finding out what complicated designs the patient can reproduce because even with 3 or 4 matches it will be obvious, if the defect is present, that he is having difficulty in aligning the match sticks into the required relation with each other. And, if he succeeds in completing the first two designs he may perseverate when he comes to the third, reverting to the first or second pattern (Fig. 14). The use of Kohs' blocks as test materials presupposes that the patient

No. of Test	Arranging of sticks	Patient's copy
1.		
2.		
3.		
4.		

Fig. 14. Constructing designs with match sticks. The patient does the first two correctly but perseverates over the third design, repeating the previous one and when a fourth is set up does the same.

Richard Sydney Allison

has no defect in colour vision so it is advisable to let him familiarize himself with the different colour arrangement before setting up the simplest of the many test patterns available and inviting him to copy it. Usually, as is the case with match sticks it is seldom necessary to proceed far because constructional difficulty often declares itself by inability to bring four blocks together so as to form a square. In other instances an apraxic patient, obviously perplexed, will work away conscientiously but always failing to insert the last block correctly into the design. At this stage he gives up in disgust, declaring that it is a "child's game" and it is a long time since he left school, or, he may proceed to undo the design and begin all over again, a sequence suggestive of perseveration but which the classically-minded Pineas dubbed very aptly the "Penelope syndrome".

Disturbance of Body Awareness or of the *body schema* so that a patient denies that his leg or arm belongs to him are observed only with posteriorly extending (chiefly vascular) lesions involving the parietal region of the non-dominant hemisphere and causing left-sided hemiplegia and hemianaesthesia – the so-called autotopagnosia. In a more bizarre form in which visual field defects are often superadded, the patient may stoutly deny his hemiplegia and other defects and declare he is perfectly fit (anosognosia).

A good illustration was seen some years ago in a woman of 76 years who for some weeks after a stroke, during which there was persistent light clouding of consciousness, denied repeatedly that her left arm and leg belonged to her. When the left arm was held up and her gaze directed to it she still persisted in her denial and even confabulated making out that the arm was a baby which someone had placed in bed beside her.

The combination of *finger agnosia*, inability to form the shape of the symbols used in *writing*; loss of understanding of arithmetical symbols and of the place value of digits, *acalculia*, and *right-left bodily disorientation*, like constructional apraxia, can all be demonstrated in patients showing general clouding of consciousness and it is only when the patient is otherwise lucid that the persistence of these disabilities has diagnostic value in pointing to a parietal lesion. In my own series of 18 cases the lesion responsible was found in the left parietal lobe more often than in the right, but two of the patients had tumours confined to the frontal region. Originally when Gerstmann first described inability to name or to identify the fingers, R-L disorientation, agraphia and acalculia, he concluded on the basis of anatomical pathological studies that the tetrad of symptoms was

distinctive of a lesion affecting the dominant parietal lobe in the region of the angular gyrus but this view is no longer held. What can be said with confidence, however, is that when two or more of the symptoms are present this does point to organic brain disease and that, when there is no associated general clouding of consciousness, the dominant parietal lobe is likely to be the site of the disturbance.

* * *

And now to conclude, because time, even on this privileged occasion, does not license me to dwell longer on a favourite topic. Little new has been added but you will have discerned that moving from alligators to spacemen and using the parietal cortex as a sounding-board, my chief purpose has been to stimulate interest in this comparatively new branch of the neurological sciences.

I am old, but not too old, to recognise that neuropsychology is still too encumbered by complex and strange sounding terms, most of which possess only descriptive value and belong to an age when the neurologist, the psychiatrist and the psychologist each led his own blinkered and separate existence. Neurosurgery acted as the catalyst which drew them together and our concepts are well summed-up by one of its chief apostles, Dr. Wilder Penfield.

"Sensation and movement and speech and perception are not located in special areas of the cerebral cortex. But there are cortical areas that can be delineated with increasing exactness for each of these functions.... In each of them one may identify the neurone transactions without which the corresponding mental phenomena are impossible.

"The actions of each mechanism depends upon the cortical area, together with its connexions to underlying thalamus and other parts of the higher brain stem. Interfering with brain stem action results in unconsciousness.

"Cortical removals deprive a man only of one or more of his functional capacities. These are facts, not theories."

To-day, with so much technical aid available, the field should have an increasing appeal to many young men, already versed in orthodox clinical neurology. For those whose paths lie in the broader tracts of medicine and surgery, one can say without exaggeration that some acquaintance with neuropsychology is indispensable if the error is not to be made of assuming that bizarre and diverse symptoms, such as I have described, must necessarily be interpreted as evidence of widespread and irreversible brain disease.

Richard Sydney Allison

I began life as a physician and will never depart from its discipline. If in later years I became especially interested in the topics we have been discussing, this can only be explained by the encouragement offered to me initially by two of my former chiefs, both Past Presidents of this Society, William Calwell and W. W. D. Thomson, and by my former colleagues, Cecil Calvert and Hilton Stewart, with whom I enjoyed so many happy hours. It has been a long road since the moment in 1930 when I came back to Belfast and paid a visit to Professor Tom Milroy in the old Physiology Department at Queen's. He wanted to know what I had been doing and when I told him: "Medicine with a special interest in neurology," he looked at me in disapproval, but not unkindly, before commenting: "Neurology is a subject in which it is not enough to be interested, one must be engrossed in it."