

Percival Templeton Crymble (1880–1970)

President of the Ulster Medical Society

1936–37

Presidential Opening Address

Ulster Medical Society

October 1936

THE DUODENUM AND ITS SURGERY.

APPLIED ANATOMY

The duodenum is one of the most interesting of the abdominal viscera; it is linked up with numerous pathological conditions, and is of interest to the physician, the surgeon, and the pathologist.

Developmentally it may be the seat of an atresia, or it may show diverticula along its pancreatic border, especially in the region of the ampulla of Vater, but it should be noted that these diverticula are never found in the first part. Its relation to the vertebral column renders it liable to traumatic rupture, where the third part may be crushed against the lumbar vertebrae, and its relation to the superior mesenteric vessels suggests the possibility of compression of the third part and dilatation of the portion lying on its oral side.

The gall-bladder and duodenum are intimately related. The second part lies in contact with the gall-bladder, and here adhesions may form, an abscess may develop, gall-stones may be discharged intraperitoneally or into the duodenum, and fistulae may develop between the viscera or between the viscera and the abdominal wall.

The common bile-duct descends behind the first part and medial to the second part, finally opening at the ampulla of Vater, four inches from the pylorus. The duct may be blocked by a stone, the removal of which may require mobilization of the second part, or may lead to a transduodenal choledochotomy. Anastomosis of the gall-bladder to the second part is indicated for common duct obstruction by pancreatic tumour, whilst a tumour of the bile papilla may be removed locally, or may justify a free removal of the second part and an implantation of the common duct into the first part.

Apart from these anatomical relations, easily visualized and easily explained, there are other links between the two viscera, such as the combination of cholecystitis and duodenitis, the occurrence of gastro-duodenal haemorrhage after gallbladder operations, pylorospasm secondary to gall-stones,



and duodenal symptoms relieved by cholecystectomy. These, perhaps, fall into the zone of applied physiology rather than that of applied anatomy.

Although the duodenum is exceedingly well supplied by blood-vessels derived from the hepatic and superior mesenteric, there is only one vessel of applied importance, and that is the gastro-duodenal artery. It is about the size of the radial, and descends behind the first part of the duodenum just lateral to the lesser sac, and in front of the pancreas. Here it is ideally situated to give copious haemorrhage into the floor of a posterior duodenal ulcer, and this vessel is always the cause of fatal duodenal haemorrhage. The vessel may be encountered by a surgeon during gastrectomy, after he has divided the duodenum and is about to infold the lower end. The vessel may be sought deliberately, or it may be punctured accidentally during the infolding operation.

Finally, the form of the duodenum in the coronal plane shows wide variations from an open U to a complete ring. The latter condition may lead to an error in gastrectomy, since the duodeno-jejunal

Percival Templeton Crymble

flexure may be adherent to the first part, and may be included in the sutures infolding the duodenal stump. The flexure becomes obstructed, the duodenum distends, the upper end gives way, and death follows.

RESULTS OF DUODENAL OPERATIONS IN THE ROYAL VICTORIA HOSPITAL, BELFAST, 1928-36.

Number of cases	138
No replies	32
Operation deaths	10
Subsequent deaths	4

ANALYSIS OF CASES.

Non-obstructive ulcer	60
Obstructive duodenal ulcer	60
Perforations	14
Cancer	2
Duodenitis	2

Subtracting the deaths and 'no replies', we are left with ninety-two cases, and the present condition of these ninety-two cases is as follows: –

Very good	69
Fair	15
Poor	8

The ten operation deaths included: –

- 3 of the perforations.
- 2 aged patients (67).
- 1 cancer of the ampulla of Vater.
- 1 uraemia.

The operation mortality in duodenal ulcer worked out at five per cent.

PATHOLOGY.

Having dealt with the gross anatomy of the duodenum – and a very thorough knowledge of this region is essential for diagnosis as well as surgical interference – let us survey the possible pathological conditions. Ulcer stands supreme in importance, but it has attracted so much attention, its signs and symptoms are so well known, that I do not propose to

discuss it. A short review, on the other hand, of the gross pathology, the operative procedures, with the results of 132 cases subjected to operation, might be of interest.

The ulcer may be single or multiple, is usually limited to the first part, and most frequently attacks the antero-superior quadrant. It is on this area of mucus membrane that the squirts of gastric fluid impinge, and this may explain the selection of this site for ulcer. The upper border and the posterior surface are also commonly affected.

The ulcer may be acute or chronic, and many perforations are supposed to result from acute ulcers. An ulcer may heal, it may perforate, it may give rise to a single haemorrhage, to repeated haemorrhages, or, when the gastro-duodenal artery is perforated, to a fatal haemorrhage. It may surround itself with so much scar-tissue and oedema that obstruction ensues, with its sequelae – vomiting, loss of weight, and retention, or the formation of scar-tissue may so shorten the duodenum as to produce diverticula on the upper or lower border, just as a concertina, when compressed, produces bulgings of the fabric.

Whilst many points in the surgical treatment of duodenal ulcer are still debatable, there is one sheet-anchor to which we can all cling: "That a gastroenterostomy performed for duodenal obstruction following ulcer gives excellent results." By excellent, I mean something between eighty and eighty-five per cent. Because, of course, the operation is attended by a certain mortality – jejunal ulcer may ensue, gastric ulcer may ensue, and gastric carcinoma may develop. Still, to cure nine people out of ten is a very successful effort, and I know of no operation in surgery which gives such universal satisfaction to patients.

My follow-up produces forty-one very good results in this operation, with three fair results and only two poor results; whilst non-obstructive duodenal ulcer treated by gastro-enterostomy gives only twenty very good results, seven fair, and four poor results. The gross material from which these results were obtained were sixty non-obstructing ulcers and sixty obstructing ulcers. If obstruction is marked, recognition is easy: there will be loss of weight, emaciation, vomiting, and visible peristalsis. Less marked degrees of blocking may require the test-meal or the opaque meal, and these are more sensitive tests than the operation findings, but it is a question if some of these radiographic retentions are not due to spasm of the pyloric canal.

A much more difficult problem is the proper procedure in the case of the non-obstructing

Percival Templeton Crymble

duodenal ulcer which has resisted prolonged or repeated medical treatment. It would appear probable that females, old people, and those free from hyperchlorhydria, are suitable for gastro-enterostomy, whilst young males with hyperchlorhydria are the most unsuitable subjects for gastro-enterostomy, and this last group is the real point at issue in the various surgical schools. This is the field for physiological gastrectomy, where, by removing half the stomach and leaving the pyloric end, acidity is diminished and anaemia is prevented. Here also is a possible indication for a local excision of a suitably placed ulcer, followed by a reconstructive pyloroplasty. Much will depend on the actual situation of the ulcer and the presence or absence of some extra-duodenal exciting cause such as a chronic appendix, an inflamed gall-bladder, an ileal kink, a dolichocolon, or septic teeth.

Strange to say, the duodenum is remarkably free from cancer. Duodenal ulcer shows no tendency to become malignant, and it is a most remarkable picture to see the way a gastric cancer refuses to cross the duodenal threshold. Cancer is found, however, in the region of the bile papilla.

A recent paper by Somervell and Orr in the "British Journal of Surgery" (October, 1936), has some interesting observations on the etiology of duodenal ulcer in South India. In Travancore, for example, where the natives live on tapioca and rice – a diet deficient in vitamins A, B, and C – duodenal ulcer is six hundred times more prevalent than in Northern Punjab, where the people have a very well balanced diet.

The function of vitamin A is to maintain the functional integrity of the cells covering the body-surfaces. The vitamin deficiency lowers the defences of the mucosa, leads to an invasion of it by bacteria, with a production of a duodenitis and ulcer.

This is by no means the only etiological theory in existence, since we already have the familial tendency, the acid factor, the embolic, the anatomic, the toxic, and the neurogenic, but it does seem to bulk largely in certain parts of India.

BAD RESULTS FOLLOWING GASTRO-ENTEROSTOMY.

From a study of the literature one would conclude that the whole story could be summed up in the words – *jejunal ulcer*; but in my somewhat small collection of cases, jejunal ulcer has occurred only twice, and in both cases a jejuno-colic fistula had resulted. This very unpleasant complication yielded to the operation of separating the jejuno-colic adhesion and closing the two apertures. The original gastro-enterostomy was left intact, and both patients

were cured of all symptoms. I have seen one perforated jejunal ulcer following a gastro-enterostomy by another surgeon, which gave a good result with simple closure.

Gastric Ulcer as a Sequel. – I have met with this condition on two occasions – a large gastric ulcer developing in the presence of a gastro-enterostomy. In both cases the gastro-enterostomy had been performed by another surgeon, and the ultimate pathology was disclosed at the operation of gastrectomy.

INFLAMMATION OF THE STOMA WITH HAEMORRHAGE.

This was a most instructive case, and demonstrated the controlling effect of a gastro-enterostomy on a duodenal ulcer.

In 1917 gastro-enterostomy was performed for duodenal ulcer, and the patient remained well for seven years, when pain and bleeding reappeared. In 1927 I saw him with Dr. Unsworth, and we decided that he must have a jejunal ulcer. The gastro-enterostomy was undone, no jejunal ulcer was found, the margin of the stoma was red and inflamed-looking, and there was no duodenal ulcer. He remained quite well for one year, when pain and bleeding returned. In 1930 a two-third gastrectomy was performed, and a duodenal ulcer was recognizable. Up to the present he has remained free from symptoms.

CANCER FOLLOWING GASTRO-ENTEROSTOMY.

In 1931 I performed gastro-enterostomy on a man aged 57, who had suffered for ten years with pain and vomiting. He was found to have an obstructing duodenal ulcer. Five years later he had developed a cancer of the stoma and adjacent stomach. Mr. Woodside performed gastrectomy, and up to the present the patient has remained well.

I know of one case in whom a pyloric carcinoma developed in the presence of a gastro-enterostomy of many years' standing.

One cannot help regretting that these two cases did not have gastrectomy performed instead of gastro-enterostomy.

HAEMORRHAGE.

I have seen one death from haemorrhage, some months after gastro-enterostomy had been performed for a well-developed duodenal ulcer. Whether the bleeding came from the old duodenal ulcer, or from a secondary ulcer in the jejunum or stomach, is unknown. The immediate result of the operation was good.

VOMITING.

One of my cases died of persistent vomiting, and the obstruction appeared to be at the distal jejunal

Percival Templeton Crymble

opening. Somervell and Orr advise the passage of a nasal stomach-tube, which must be guided intra-abdominally through the obstructed place into the jejunum. In this case the stoma was perfectly patent, but the jejunal exit from the stoma region was not functioning, although the finger could be passed quite freely through it both before death and after. The blood-urea was very high before death (278 mgm.), and I am not sure of the relative proportions of obstruction and uraemia.

PYLOROPLASTY.

Occasionally one is in doubt at operation as to the presence of a duodenal ulcer. There may be a white area on the external surface, or a small palpable thickening. Rather than subject a patient to an unnecessary gastro-enterostomy, it is much wiser to open the pyloro-duodenal region boldly and inspect the interior. If no ulcer be present, the incision can be sewn up transversely; if an excisable ulcer be present, it can be excised, and the opening sewn up transversely. These are both very useful manipulations, and can be done with very little danger to the patient. More elaborate forms of pyloroplasty have been introduced, not only for duodenal ulcer, but also for pyloric hypertrophy and pyloric spasm. In one of these, suitable for spasm or hypertrophy, one carries out extramucous resection of the anterior half of the pyloric sphincter. In another, the whole thickness of the pyloro-duodenal wall is removed, plus an ulcer from the anterior half of the canal, and a new opening reconstructed by transverse suturing. This is a direct operation for duodenal ulcer, and the Mayo Clinic advise it for young patients with a non-obstructing ulcer on the anterior wall, who have marked hyperacidity and a high-lying hypertonic stomach. It is also suitable for cases of duodenitis, and direct attack should be considered in those cases where haemorrhage has been prominent. The contra-indications for direct operation will depend upon the accessibility of the duodenum, and the extent and nature of the pathology (e.g., posterior ulcer, extensive scarring, or multiple ulcer). At present, in the Mayo Clinic, thirty per cent. of duodenal ulcers are being treated by local excision and some form of pyloroplasty or duodenectomy, but in the past most of the cases were treated by gastro-enterostomy.

DUODENAL HAEMORRHAGE.

Some physicians claim that they have never seen a death from haematemesis, and it is perhaps unreasonable to expect any physician, who has watched thirty or forty consecutive cases of haemorrhage recover, to call in a surgeon except in one of those rare cases where in spite of transfusion

and medical treatment no progress is being made. It is therefore likely in this country that the surgeon's appearance will be late, and at a time when gastrectomy will carry a high mortality. Severe duodenal bleeding sufficient to cause death is nearly always from the gastroduodenal artery, and if this vessel could be ligatured, proximal and distal to the bleeding spot, the bleeding should be controlled. This vessel can only be clearly demonstrated after division of the duodenum, but it should be possible to ligature it above and below the first part of the duodenum without opening the bowel. Fatal gastric haemorrhage is almost always from the left gastric artery, and here again it might be possible to ligature the vessel above and below the ulcer.

When one operates for gastro-duodenal bleeding, the first thing to do is to determine the presence of a lesser curve or duodenal ulcer. If these are absent, then no operation should be necessary; if one or other be present, then ligatures should be applied to the suitable vessel. If the patient's condition permits, a gastrectomy should be done, and during this the vessel which is the cause of the bleeding can be ligatured. Previous X-ray examination may point to the source of bleeding, and a normal radiogram would exclude any surgical interference. A sharp haemorrhage in a known case of duodenal or lesser-curve ulcer should be a warning signal to the physician. It is apt to recur; a large vessel is involved, and the surgeon should be called in early.

GALL-STONES AND THE DUODENUM.

Large gall-stones may erode the adherent walls of the gall-bladder and the second part of the duodenum, and may escape along the bowel, or, if sufficiently large, the stone may be held up in the lower ileum and produce acute intestinal obstruction. The very large stones which block the colon or rectum must escape direct from the gall-bladder into the transverse colon. The real pathology is often missed in these cases, as the abdominal colic and vomiting is put to the credit of gall-stones in the gall-bladder.

Once the stone has escaped into the duodenum, the fistula tends to close. The gall-bladder may perforate, stones may escape, and an abscess cavity, partially walled off by the duodenum, may form. In one of my cases, stones were removed from such a cavity, and ten days later the wall of the duodenum gave way with the formation of a fistula. The patient died a few days later.

CARCINOMA.

A carcinoma of the ampulla of Vater is a most serious condition. The early onset of jaundice brings

Percival Templeton Crymble

the patient to the operating-table when the growth is still small, but the operation of a duodenectomy is so complicated by an implantation of the common duct, and no satisfactory way of dealing with the pancreatic duct, that the mortality is high. In one case a pedunculated adeno-carcinoma was removed trans-duodenally. This operation was in 1934, and the patient is still well. In a second case, where the duodenal wall was extensively involved and jaundice had been present for some months, I removed the second part of the duodenum, closed the proximal and distal ends, did a gastro-enterostomy, and implanted the liver end of the common bile-duct and the pancreatic duct into the stomach. Death followed in five days.

FOREIGN BODIES.

Whereas removal of foreign bodies from the stomach is a fairly common procedure, and one which is easy to do and attended with very little risk, it is quite otherwise with the duodenum. Materials which pass the pylorus usually escape along the bowel and are passed naturally. A hair clip, known as Kirbi's grip (two to two and a half inches long), is occasionally swallowed, passes through the pylorus, but seems unable to circumnavigate the bends of the duodenum. It is apt to lodge in the second part, and may require surgical removal. It can usually be milked back into the stomach and then removed through a small gastric incision. I have met one such case in the Belfast Hospital for Sick Children.

MEGALODUODENUM, ETC.

I have never yet been called upon to operate for megaloduodenum, or true congenital diverticulum. Out of 114 true diverticula seen in the Mayo Clinic, only four were thought worthy of operation. Most of the diverticula admitted to our wards in the Royal Victoria Hospital involve the first part, and are secondary to duodenal ulcer.

Megaloduodenum requiring operation must be a comparatively rare condition, since I have never yet knowingly encountered one. An occasional brilliant result has been achieved by duodeno-jejunostomy, but in many cases the result is disappointing.

A duodenum may be dilated, and the seat of stasis in the absence of any mechanical obstruction; in others the superior mesenteric vessels are supposed to cause obstruction by pressure; whilst in a third group, a congenital atresia, a tumour, or abnormal peritoneal bands, give a clear explanation of the obstruction.

The type of individual in whom one would suspect this condition is the under-nourished person who suffers from bilious headaches and vomiting. If

the radiogram reveals stasis in a dilated second part of duodenum, the diagnosis – chronic duodenal ileus – may be made. It is only in the presence of marked symptoms that operation – duodeno-jejunostomy – should be suggested, since this condition is found in poor surgical material. They are asthenic, have migraine, low blood-pressure, and suffer from abnormal motility of other organs. The duodenal symptoms comprise a relatively small part of the picture.

The duodenum may be obstructed by congenital stricture or by tumour growing in the wall. It may also be obstructed by pressure from without – for example, congenital anomalies such as faulty rotation or abnormal peritoneal bands or adhesions, and again by post-operative bands and adhesions. In one very interesting case, described by Foucar in 1923, there was duodenal obstruction produced by a chronic volvulus of the small bowel, the twisted mesentery compressing the duodenum. At a recent post-mortem examination in the Royal Victoria Hospital there was a dilated duodenum and much dark-coloured small bowel. There was no mesenteric thrombosis or embolus. The man was jaundiced, and no explanation of the jaundice could be found. Could a volvulus be a possible explanation of his bowel condition? I believe it is possible to undo a volvulus, unwittingly, during an operation or a post-mortem examination. Thickening of the mesentery by tuberculous glands can also cause duodenal obstruction, but it must be exceedingly rare, since we have not met the condition in the Belfast Hospital for Sick Children, where we meet many cases of tabes mesenterica. Perhaps we have failed to recognize the condition.

CLOSURE OF THE DUODENAL STUMP.

This is one of the commonest operations on the duodenum, since it forms one of the steps in most forms of gastrectomy. According to some authorities, it is leakage from this stump which is the usual cause of death following gastrectomy. The inaccessibility, the shortness, the friability, the incomplete peritoneal covering, and the close proximity of the pancreas and gastro-duodenal vessels, all militate against a perfect infold. To overcome all these difficulties, and to prevent, at the same time, leakage of duodenal contents and bleeding, suitable instruments and careful technique are required. I have not found the ordinary textbook method satisfactory – applying crushing forceps, dividing the duodenum on the oral side to these, suturing the duodenum over the forceps by a continuous suture, removing the forceps, and tightening. The crushing clamp is too bulky, the continuous suture may leave a loose loop, or the

Percival Templeton Crymble

suture may refuse to tighten. For many years I have used a Martel's clamp for dividing the duodenum, the pylorus, or the stomach. It consists of three pairs of blades which can be compressed by a clamp and held in position after removing the clamping device. Each pair of blades can be released separately. First one releases the middle blades; then the duodenum or stomach is divided close to the oral blades, and that leaves a crushed fringe of duodenum, which can be sutured with perfect ease and comfort. The vessels on the upper and lower border of the duodenum are now ligatured a short distance from the clamp, and a pair of fine Pringle colon-forceps are applied to the duodenum, immediately anal to the duodenal blades of the Martel. When the Pringle forceps are in position, one releases the duodenal blades of the Martel. The Pringle forceps are now used to infold the stump, and this is done with a continuous suture. In a recent case, owing to shortness of the stump and inaccessibility, I found it impossible to infold, and I rotated the forceps through 180 degrees and fixed the stump in this position. The patient made an excellent recovery, so that presumably there was no leakage.

The oral blades of the Martel remain on the stomach, and are removed with the specimen.

Donati's clamp, of which I have no experience, corrugates the duodenum, and permits a straight needle to be passed through the corrugated portion, drawing a thread after it. On removal of the clamp, this thread is tightened, and a suitable stump for infolding is produced.

In conclusion, I should like to return my grateful thanks to Mr. J. W. Millen for his assistance in collecting the material used in the follow-up.

Percival Templeton Crymble

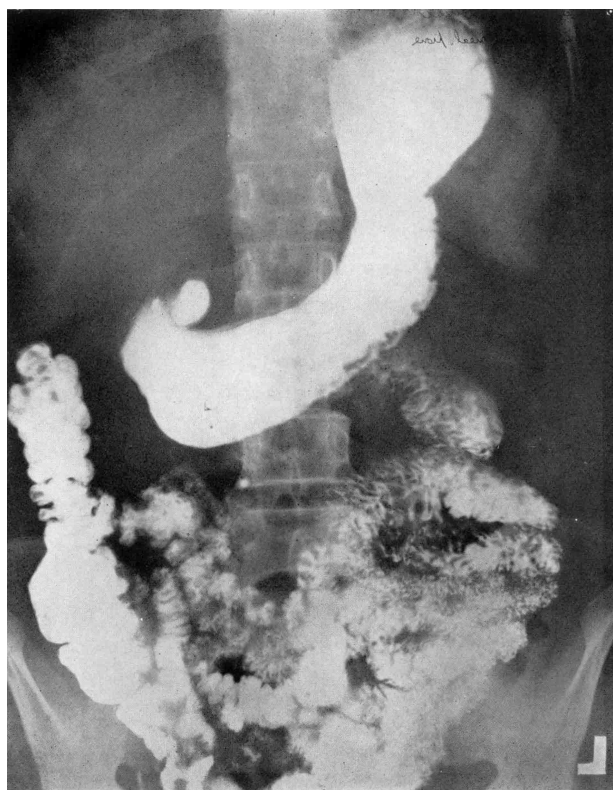


Fig. 1. Radiogram of stomach and duodenum showing a diverticulum of the first part of the duodenum. The operation revealed a duodenal ulcer, and the diverticulum was secondary to this ulcer. The pathological area was infolded and a gastro-enterostomy performed.

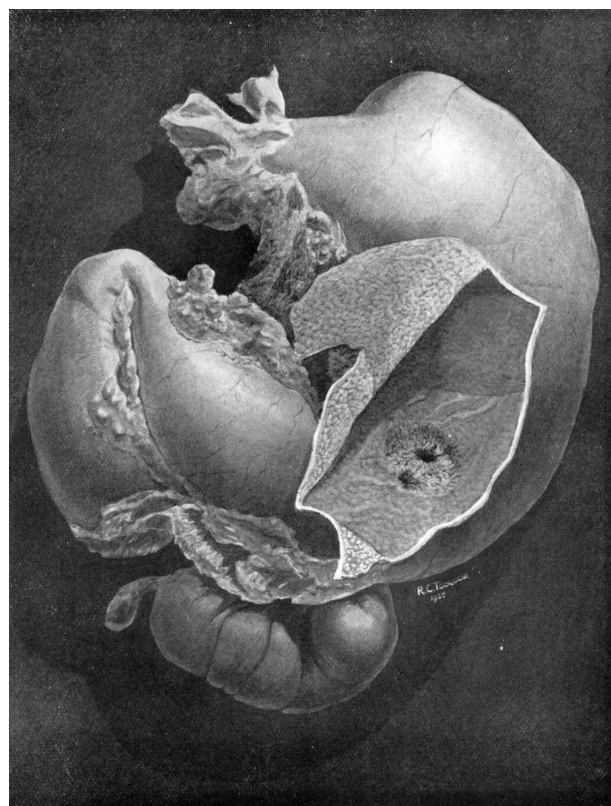


Fig. 2. Dilatation of the stomach and duodenum following gastro-enterostomy for duodenal ulcer. The stomach has been opened to show the stoma. The gastro-enterostomy was quite patent, and the obstruction appeared to be at the distal jejunal orifice,

Percival Templeton Crymble



Fig. 3. The pylorus and adjacent portion of the duodenum have been crushed between the blades of the Martel clamp. A large branch of the gastroduodenal artery, passing to the gastro-colic ligament, is hooked forwards on an aneurism needle. A large aperture has been torn in the bloodless part of the lesser omentum in the application of the clamp, and the caudate lobe of the liver is lying exposed. The right part of the lesser omentum (hepatoduodenal ligament), containing the hepatic artery, common bile-duct and portal vein, is seen to be intact. The inferior surface of the liver with the gall-bladder, is seen.

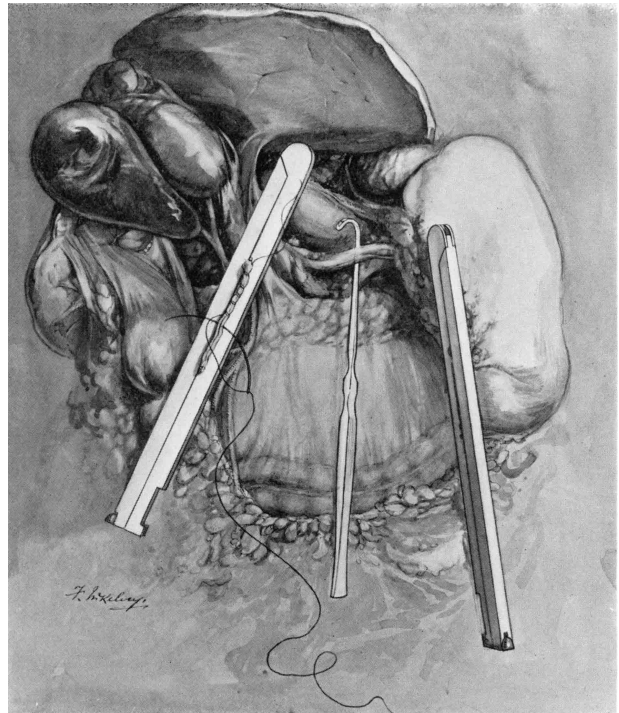

Fig. 4. The central blades of the Martel clamp have been removed and the crushed viscus divided close to the gastric blades. A segment of crushed duodenum, projecting beyond the duodenal blades, is being sutured by continuous forty-day No. 00 catgut. The left gastric vessels are hooked forward by a needle. The body of the pancreas lies exposed. The gastric blades of the clamp remain in position until the stomach has been removed.

Percival Templeton Crymble

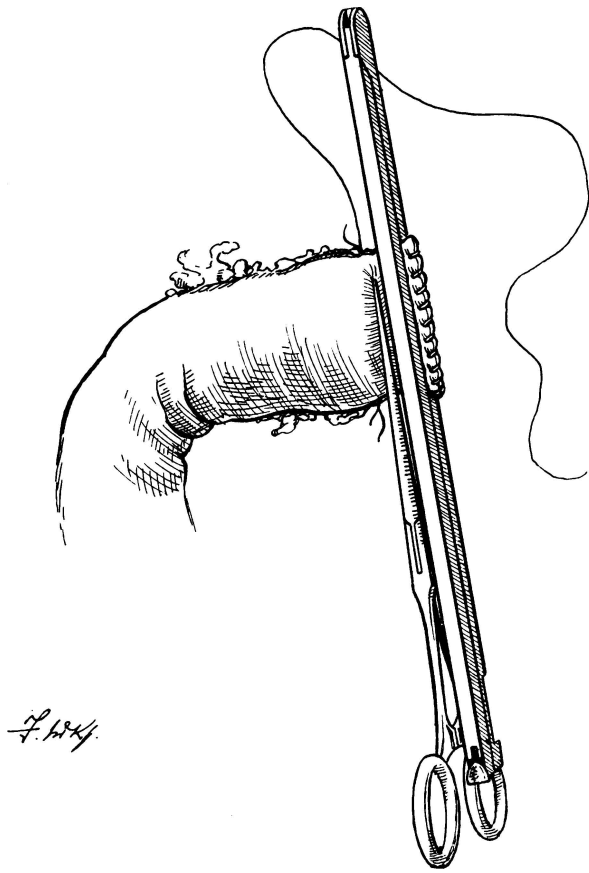


Fig. 5. The duodenal blades of the clamp are in situ, and the crushed edge of the duodenum has been controlled by a continuous suture. The vessels on the upper and lower margin of the duodenum have been ligatured by a twenty-day No. 1 catgut, and the upper ligature has been left long for use subsequently in the infolding. A fine Pringle clamp has been applied to the duodenum, close to the Martel blades. This clamp prevents the duodenum retracting after removal of the Martel blades, and is of use in the process of infolding the duodenal stump.

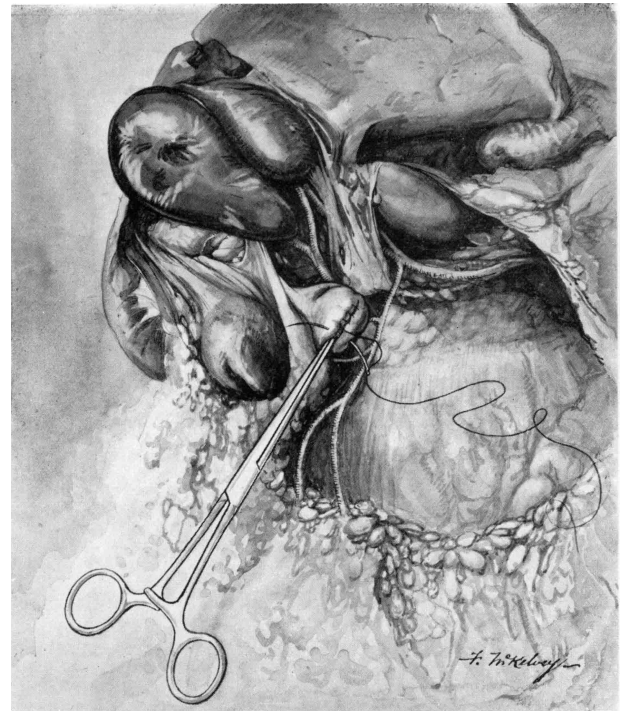


Fig. 6. The Pringle clamp has infolded the duodenal stump, and the infolded position is maintained by a sero-muscular continuous suture. This suture begins by tying the vessels on the upper margin of the duodenum, and during its insertion the clamp is released once or twice, shifted downwards, and reapplied. This enables one to recognize any uncontrolled vessel, and permits the tightening of the suture step by step.

The gastro-duodenal artery giving off the right superior and inferior pancreatico-duodenal branches is demonstrated.